

# Parvovirus-Associated Anemia in a Renal Transplant Recipient Adolescent

## *Renal Transplant Alıcısı Adölesan Hastada Parvovirüs İlişkili Anemi*

### ABSTRACT

Anemia is a frequent problem in renal transplant recipients, the most frequent cause being erythropoietin deficiency due to allograft failure. Parvovirus B19 can cause persistent viremia and erythropoietin resistant erythroid aplasia in immunosuppressed patients. On the other hand, it can cause allograft dysfunction in renal transplant recipients. A male patient with end-stage renal failure due to Alport syndrome received a renal transplant at 17 years of age. A triple immunosuppressive treatment with prednisolone, tacrolimus and mycophenolate mofetil was then initiated. A graft biopsy was performed because of >30% increase in serum creatinine and development of anemia (Hb 6,9 g/dL) during the early posttransplant period, but it was not consistent with acute rejection. Anemia-related assessments revealed reticulocytopenia and erythroid aplasia on bone marrow aspiration. Blood parvovirus B19 PCR level was found to be 7.270.278.211 IU/mL. Immunosuppressive drug doses were held constant and IVIG treatment was instituted for 5 days. After this treatment, the hemoglobin level increased to 10.0 mg/dl and 13.2 mg/dL at the 2nd week and 2nd month, respectively. In conclusion, when anemia develops in renal transplant recipients in the absence of rejection and hemolysis, parvovirus infection should be considered.

**KEY WORDS:** Anemia, Parvovirus, Renal transplantation

### ÖZ

Böbrek transplantasyonu uygulanan hastalarda anemi sık görülen bir sorundur ve en sık nedeni graftın işlev görmemesine bağlı eritropoetin yetersizliğidir. Parvovirüs B19 immünsuprese hastalarda kalıcı viremiye ve eritropoetine dirençli eritroid aplazisine yol açabilir. Öte yandan, parvovirus B19 böbrek transplant alıcılarında allograft disfonksiyonuna da neden olabilir. Burada parvovirüs enfeksiyonu ilişkili anemi gelişen renal transplant alıcısı bir hasta sunulmuştur. Alport sendromuna bağlı son dönem böbrek yetmezliği gelişen erkek hastaya 17 yaşında kadavradan renal transplantasyon yapıldı. Prednizolon, takrolimus ve mikofenolat mofetil ile üçlü immünsupresif tedavi başlandı. Erken post-transplant dönemde serum kreatinin düzeyinde %30'un üzerinde artış olması ve anemi gelişmesi (Hb 6.9 g/dL) üzerine akut rejeksiyon düşünülerek yapılan graft biyopsisinde rejeksiyon bulgusu saptanmadı. Anemi için yapılan tetkiklerinde retikülositopeni ve kemik iliğinde eritroid aplazisi belirlendi. Kanda Parvovirüs B19 PCR ile 7.270.278.211 IU/mL olarak belirlendi. İmmünsüpresif ilaç dozlarında değişiklik yapılmadı ve beş gün süre ile IVIG tedavisi uygulandı. Tedavi sonrası hemogloblin düzeyi ikinci haftada 10,0 g/dL, ikinci ayda ise 13,2 g/dL'ye kadar yükseldi. Sonuç olarak, renal transplant alıcısı hastalarda anemi geliştiğinde rejeksiyon ve hemoliz bulguları yok ise parvovirüs enfeksiyonu olasılığı göz önünde bulundurulmalıdır.

**ANAHTAR SÖZCÜKLER:** Anemi, Parvovirüs, Renal transplantasyon

**Seçil ARSLANSOYU ÇAMLAR<sup>1</sup>**

**Alper SOYLU<sup>1</sup>**

**Şebnem YILMAZ BENGÖA<sup>2</sup>**

**Mehmet Atilla TÜRKMEN<sup>1</sup>**

**Salih KAVUKCU<sup>1</sup>**

1 Dokuz Eylül University Faculty of Medicine, Department of Pediatrics, Division of Nephrology, İzmir, Turkey

2 Dokuz Eylül University Faculty of Medicine, Department of Pediatrics, Division of Hematology Oncology, İzmir, Turkey



Received : 08.03.2015

Accepted : 22.11.2015

Correspondence Address:

**Seçil ARSLANSOYU ÇAMLAR**

Dokuz Eylül Üniversitesi Tıp Fakültesi, Çocuk Nefrolojisi Bilim Dalı, İzmir, Turkey

Phone : +90 232 412 61 99

E-mail : secilars@yahoo.com

## INTRODUCTION

Anemia is a problem observed in almost 40% of renal transplant recipients (1). The most frequent cause is erythropoietin deficiency due to graft dysfunction. Other causes of anemia during early post-transplantation period include acute rejection, acute and chronic blood loss, bone marrow inhibition due to immunosuppressive or antiviral drugs, and viral infections such as CMV, EBV, HIV and human parvovirus B19 (HPV B19) (1,2).

HPV B19 is a single-stranded DNA virus from the parvoviridae family (3). Even though HPV B19 infections are generally asymptomatic, it can also cause aplastic crisis in patients with rheumatologic diseases, sickle cell anemia, hydrops fetalis and erythema infectiosum in children. HPV B19 may lead to persistent viremia and erythropoietin resistant erythroid aplasia in immunosuppressed patients (2,4). In patients with renal transplantation, it may trigger acute rejection and also chronic allograft dysfunction.

Herein we present a case of HPV B19 related anemia in an adolescent renal transplant recipient who responded to intravenous immunoglobulin (IVIG) treatment.

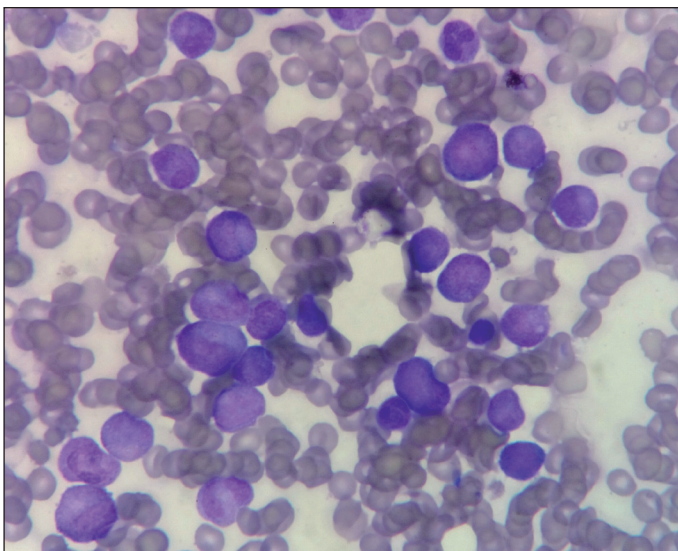
## CASE REPORT

Our male patient was diagnosed as Alport syndrome due to microscopic hematuria at the age of 6 years. Chronic hemodialysis program was initiated at the age of 15 years upon development of end-stage renal disease. At the age of 17 years, he received a cadaveric kidney transplant. Triple immunosuppressive treatment with prednisolone, tacrolimus and mycophenolate mofetil was then initiated. At the post-transplantation second week, serum creatinine increased from 1.0 mg/dL to 1.36 mg/dL and the hemoglobin decreased from

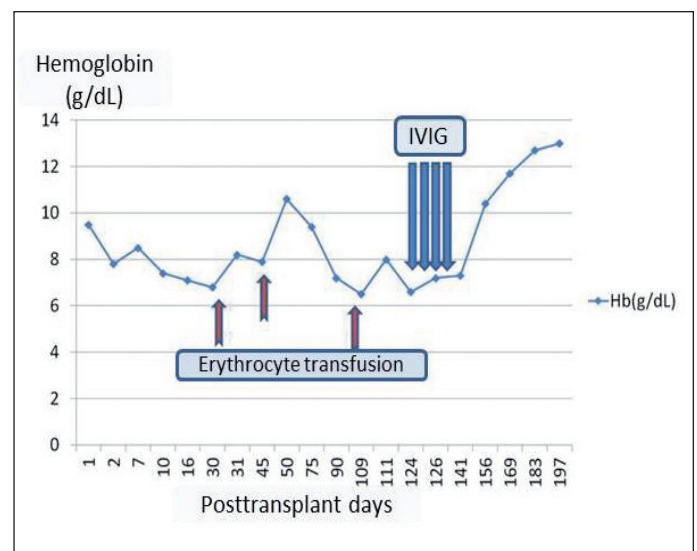
9.5 g/dL to 8 g/dL. He was thought to have acute rejection, and three days of pulse methylprednisolone treatment was initiated. Serum creatinine did not increase any more but did not decrease to below 1.1 mg/dL. Serologic examinations for CMV, EBV, and BKV were negative. Anemia, on the other hand, persisted and became even more prominent (hemoglobin decreased to 6.9 g/dL at post-transplantation 3<sup>rd</sup> week). Anemia-related assessments revealed normochromic normocytic erythrocytes on peripheral smear, low (0.04%) reticulocyte count, negative antiglobulin test, and normal serum iron and ferritin levels. Recombinant human erythropoietin (rhEPO) treatment was initiated with no response. Bone marrow aspiration revealed erythroid aplasia (Figure 1). Aplastic crisis was suspected and HPV B19 infection was investigated. Polymerase chain reaction (PCR) for HPV B19 revealed a DNA copy number of 7.270.278.211/mL. Thus, the patient was diagnosed as HPV B19 associated aplastic anemia. As serum creatinine did not decrease to baseline level, a kidney biopsy was performed and no sign of acute rejection was detected. Erythropoietin treatment was stopped, immunosuppressive drug doses were held constant and 400 mg/kg/day IVIG treatment was prescribed for five days. Hemoglobin level increased to 10.2 and 13.2 g/dL at second week and second month of this treatment, respectively (Figure 2). We could not check the parvovirus PCR status of the patient after IVIG treatment.

## DISCUSSION

The target cells of HPV B19 are erythroid precursors. This virus binds to the P antigen on the surface of these cells and causes lysis of them (5). The P antigen is also expressed in many other cell types including renal and endothelial cells (3). Among the renal lesions associated with direct endothelial cell damage by HPV B19 infection, acute proliferative glomerulonephritis, Henoch-Schonlein nephritis, collapsing glomerulopathy, focal



**Figure 1:** Bone marrow aspiration revealed erythroid aplasia.



**Figure 2:** Change of hemoglobin levels of the patient with respect to post-transplant days and IVIG treatment.

segmental glomerulosclerosis, and thrombotic microangiopathy have been described (2).

HPV B19 related glomerulonephritis and thrombotic microangiopathy were also defined in renal transplant recipients and these lesions were also reported to lead to chronic allograft injury. Renal transplant recipients can acquire HPV B19 infection through the respiratory route, blood transfusion, donor organ or nosocomial ways (3). On the other hand, pre-transplant latent infection may also be activated following transplantation (1,3). For this reason, pretransplant HPV B19 assessment is recommended to be included in viral examination (5). Pre-operation parvovirus status was not assessed in our patient; hence, it is not possible to precisely distinguish between latent infection activation and new infection. However, as 73% of patients undergoing hemodialysis treatment have anti-HPV B19 IgG antibodies (3), transmission of the virus to our patient probably occurred before transplantation.

Diagnosis of the disease depends on peripheral blood and bone marrow findings, demonstration of the virus specific antibodies and of the viral DNA. IgM antibodies are produced during the acute infection, while presence of IgG antibodies shows past infection. As IgM antibody response may not develop in immunosuppressed patients (5), identification of viral DNA by PCR is important (5). A DNA copy number  $>10^7$ /mL is an indicator of active infection. Viral DNA copy number was  $7.3 \times 10^9$ /mL in our case indicating active viral replication.

The most frequent pathology during HPV B19 infection is anemia as the virus specifically infects erythroid precursor cells. Neutropenia and thrombocytopenia are also seen, though rarely. Fever, arthralgia, skin eruption, myocarditis, pneumonia and hepatitis may develop in immunosuppressed patients (6-8). Allograft dysfunction was reported in 10% of renal transplant recipients. Our patient experienced an increase in serum creatinine level along with post-transplant anemia that was attributed to allograft dysfunction due to acute rejection. However, graft biopsy did not disclose any sign of rejection. The anemia did not respond to rhEPO. Anemia resistant to rhEPO treatment was also described previously in parvoviral infections (5).

No specific antiviral drug is present for HPV B19 at the moment. Treatment modalities include IVIG, rhEPO, G-CSF, ganciclovir, and plasmapheresis (6-8). Spontaneous recovery without treatment takes place within 4-8 weeks. IVIG treatment shortens the duration of recovery (8). In renal transplant recipients, as the disease is mostly seen during the period with most severe immunosuppression (0-12 months), a reduction in immunosuppressive drug dosages has been considered (9). Prognosis for HPV B19 associated disease was reported to be poorer in patients with blood tacrolimus level  $>8$  ng/mL, while no relation was found with blood cyclosporine A level (3). In transplant recipients with proven HPV B19 disease, it is recommended that immunosuppressive drug dosage (such as mycophenolate mofetil) should be decreased if the renal functions are normal, while IVIG is recommended if renal functions are not normal (1). Since our patient had minor

renal dysfunction (serum creatinine 1.1-1.4 mg/dL), IVIG was administered without decreasing the immunosuppressive drug dosage. There is no general consensus on the proper dosage and administration duration for IVIG; however, the most frequently used IVIG protocols involve either 0.4 g/kg/day for 5 days or 1 gr/kg/day for 3 days. In one case report, 0.25 g/kg IVIG dosage was implemented for 3 days with a successful response to therapy, yet early relapses appeared to be more frequent (10). We used 0.4 g/kg IVIG for 5 days in our case. It was reported earlier that after treatment cessation, 1 out of 3 patients may show relapse, and that IVIG prophylaxis could prevent relapse for a 3-month interval (8).

In conclusion, when anemia with reticulocytopenia develops in renal transplant recipients with no sign of rejection and hemolysis, a possible parvoviral infection should be considered. The treatment of patients partly depends on the clinical setting, and additional IVIG treatment in patients with allograft dysfunction (as in our case) can lead to positive results.

## REFERENCES

1. Khameneh ZR, Sepehrvand N, Sohrabi V, Ghasemzadeh N: The seroprevalence of Parvovirus B19 among kidney transplant recipients: A single-center study. *Saudi J Kidney Dis Transpl* 2014;25:16-21
2. Waldman M, Kopp JB: Parvovirus B19 and the kidney. *Clin J Am Soc Nephrol* 2007;2:47-56
3. Xiao C, Wang CX, Liu LS, Fu Q: Clinical investigation of human parvovirus B19 infection after renal transplantation in China. *Transplant Proc* 2013;45:1593-1599
4. Čapenko S, Kozireva S, Folkmane I, Bernarde K, Rozentals R, Murovska M: Anemia as a complication of parvovirus b19 infection in renal transplant recipients. *Medicina (Kaunas)* 2012;48:299-304
5. Pinto V, Grandy J, Zambrano P, Corta B, Salas P, Salgado I, Santander J, Salgado C, Chadid J, Iniguez R: Severe anemia from parvovirus b19 infection in pediatric renal transplant recipients: Two case reports. *Transplant Proc* 2008;40:3261-3264
6. Marchand S, Tcherinia G, Hiesse C, Tertian G, Cartron J, Kriaa F, Boubenider S, Goupy C, Lecoite D, Charpentier B: Human parvovirus B19 infection in organ transplant recipients. *Clin Transplant* 1999;13:17-24
7. Eid AJ, Brown RA, Patel R, Razonable RR: Parvovirus B19 infection after transplantation: A review of 98 cases. *Clin Infect Dis* 2006;43:40-48
8. Gosset C, Viglietti D, Hue K, Antoine C, Glotz D, Pillebout E: How many times can parvovirus B19-related anemia recur in solid organ transplant recipients? *Transpl Infect Dis* 2012;14:64-70
9. Cavallo R, Merlino C, Re D, Bollero C, Bergallo M, Lembo D, Musso T, Leonardi G, Segoloni GP, Ponzi AN: B19 virus infection in renal transplant recipients. *J Clin Virol* 2003;26:361-368
10. Liefeld L, Buhl M, Schweickert B, Engelmann E, Sezer O, Laschinski P, Preuschof L, Neumayer HH: Eradication of parvovirus B19 infection after renal transplantation requires reduction of immunosuppression and high-dose immunoglobulin therapy. *Nephrol Dial Transplant* 2002;17:1840-1842