

Scintigraphy as a Reliable Technique for Diagnosis and Follow-Up of Pleuroperitoneal Leakage in Peritoneal Dialysis Patients

Periton Diyalizi Hastalarında Plevroperitoneal Kaçağın Tanı ve Takibinde Güvenilir Bir Teknik Olarak Sintigrafi

ABSTRACT

Metabolic and mechanic complications can be seen due to peritoneal dialysis. Pleuroperitoneal leakage is rare but can be a life-threatening mechanic complication of peritoneal dialysis. Some techniques have been used to diagnose this entity. Radionuclide imaging can be used as a reliable technique in order to show the pleuroperitoneal passage and can be used to show the recovery. Herein we present the first case report in the literature about a patient with pleuroperitoneal shunt that was demonstrated scintigraphically during the leakage and after the resolution.

KEY WORDS: Chronic kidney disease, Peritoneal dialysis, Pleuroperitoneal leakage, Scintigraphy

ÖZ

Periton diyalizine bağlı metabolik ve mekanik komplikasyonlar görülebilir. Plevroperitoneal kaçak nadirdir fakat periton diyalizinin hayatı tehdit edici bir mekanik komplikasyonu haline gelebilir. Radyonüklit görüntüleme plevroperitoneal geçişi göstermede güvenilir bir teknik olarak kullanılabilir ve iyileşmeyi göstermede de kullanılabilir. Biz burada kaçak sırasında ve iyileşme sonrasında sintigrafi ile plevroperitoneal şantı gösterilen bir hasta hakkındaki literatürdeki ilk vaka raporunu sunmaktayız.

ANAHTAR SÖZCÜKLER: Kronik böbrek hastalığı, Periton diyalizi, Plevroperitoneal kaçak, Sintigrafi

INTRODUCTION

CAPD or APD have been used as a renal replacement modality choice for a long time. Although some complications like peritonitis frequently complicate this procedure, some rare but life-threatening complications may also occur and sensitive diagnostic measures are needed to confirm them. Tc-99m DTPA scintigraphy can be used as a reliable technique for this purpose.

CASE REPORT

A 54-year-old female with chronic renal failure due to polycystic kidney disease had been on continuous ambulatory peritoneal dialysis (CAPD) treatment for 10 years. As a consequence of coronary heart disease, she had undergone a coronary by-pass grafting operation and she was switched to hemodiafiltration for 3 days post-operatively. At the end of the 3rd day, CAPD treatment restarted. At the 10th day postoperatively,

some amount of fluid was detected in the left thoracic cavity. Biochemical tests were done and the fluid was transudative as it had the same glucose concentration as serum. A pleurocath was placed and by the 12th day there was no fluid anymore. After a 2-month asymptomatic period, she presented to the nephrology clinic with a complaint of breathlessness. Her complaint had started about one week ago and had gradually increased. The postero-anterior chest X-ray showed increased density on the left side up to the 4th rib. Thoracentesis was performed and pleural fluid was obtained. On fluid analysis, adenosine deaminase and acid-resistant bacillus tests were negative, glucose concentration was 319 mg/dl, albumin was 0.3 g/dl, total protein was 465 g/dl, LDH was 30 U/L and the concurrent serum glucose was 102 mg/dl, albumin was 3.0 g/dl, LDH was 197 U/L, and total protein was 5.7 g/dl. The cell count in the fluid was 96/mm³. Thus a shunt from peritoneal cavity to the pleural

İlhan KILIÇ¹
İlhan KURULTAK¹
Gül AKTAŞ²
Sedat ÜSTÜNDAĞ¹
Ali SARIKAYA²

- 1 Trakya University Faculty of Medicine, Department of Nephrology, Edirne, Turkey
- 2 Trakya University Faculty of Medicine, Department of Nuclear Medicine, Edirne, Turkey



Received : 29.11.2015

Accepted : 28.12.2015

Correspondence Address:

İlhan KILIÇ
Trakya Üniversitesi Tıp Fakültesi,
Nefroloji Bilim Dalı, Edirne, Turkey
Phone : +90 284 236 4981
E-mail : ilhankilic1@yahoo.com

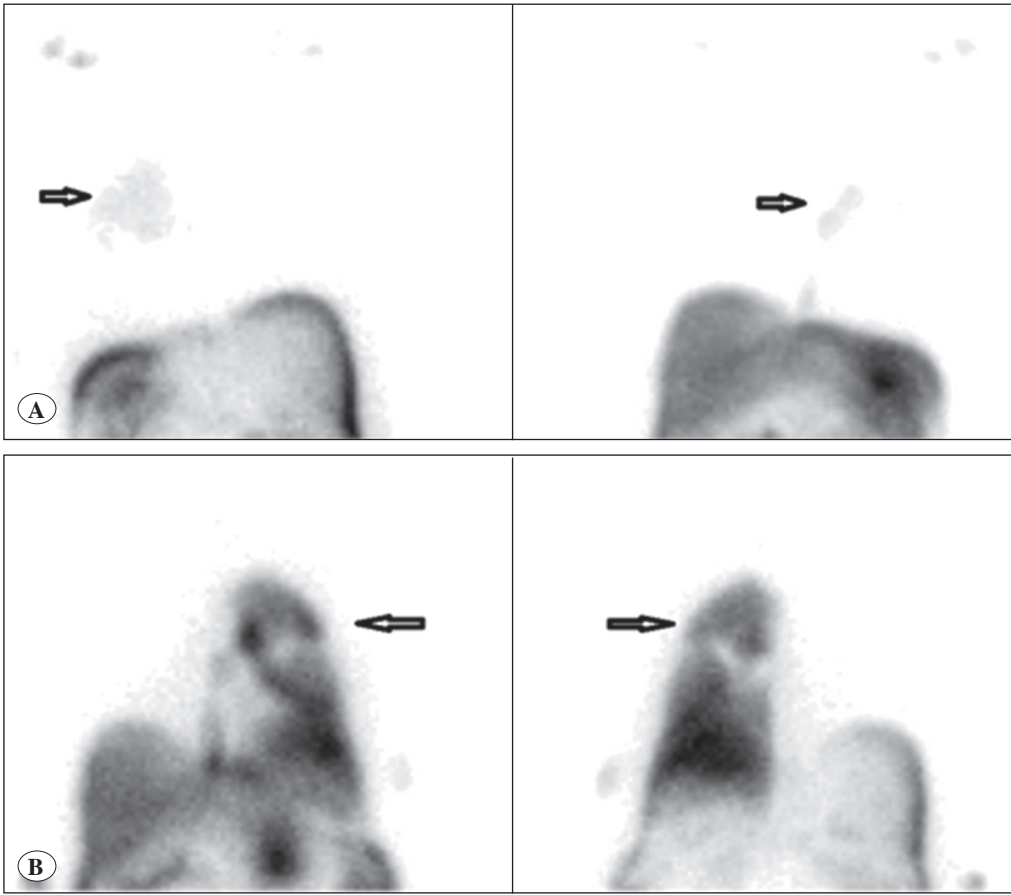


Figure 1: Radionuclide peritoneography: The scintigraphic imaging that Tc-99m DTPA is given into the abdominal cavity through the catheter after mixing with the dialysis solution.

A) Early anterior and posterior→ Activity passing mildly into the left pleural zone in the images (arrow).
B) Late (3rd hour) Activity pass that is progressively increasing confirms pleuroperitoneal leakage in the images.

space was suspected and we decided to perform scintigraphic imaging in order to verify this. Tc-99 scintigraphy with 5 mCi DTPA infusion was performed using a cannula after filling the abdominal cavity with dialysate solution. The result was that the activity in the peritoneal fluid passed into the left thoracic cavity at the early and specifically delayed sessions. In order to provide time for healing, peritoneal dialysis was postponed and hemodialysis thrice weekly was begun. After three weeks, CAPD was commenced with a lower amount of dialysate. The dialysate volume was increased gradually to the preoperative amount but the pleural effusion did not recur.

DISCUSSION

Patients with polycystic kidney disease (PKD) are more prone to pleuroperitoneal leakage as a complication of CAPD (2). Increased intraabdominal pressure as well as weakness of connective tissues and also weakness of the diaphragm are considered to play a role together. Our patient had chronic kidney disease due to PKD but until the surgery she did not have any pleural effusion episode. Although data from the literature suggest most of the pleuroperitoneal leakage syndromes occur in the right side (1), our patient's fluid was left-sided despite the anatomic barrier created by the heart on the left side.

Patients under dialysis treatment frequently have pleural effusions due to hypervolemia. This complication can usually be

treated by salt restriction and increasing the ultrafiltration volume (1). However if pleural effusion is a result of pleuroperitoneal leakage, increasing ultrafiltration by using higher osmolar and higher amounts of dialysate may increase the leakage. Symptoms can be mild but abrupt collection of large amounts of fluid can be life threatening. The presence of acute respiratory distress requires urgent drainage of fluid by thoracentesis. Symptomatic pleural effusion occurred in our patient about two months after the coronary by-pass operation. She presented with shortness of breath. On chest X-ray, there was some fluid on the left thoracic cavity. She was deoxygenated and thoracentesis for drainage of pleural fluid was performed quickly. After intervention, the collected fluid was analyzed in order to make a differential diagnosis. Light's criteria were used and the fluid was identified as transudate and was microscopically clear and the ADA test was also negative. The glucose concentration was 319 mg/dl in the pleural fluid sample although the serum level was 106 mg/dl. It was decided to perform DTPA scintigraphy in order to determine if pleuroperitoneal leakage was the etiology.

Diagnosis can be made by computed tomography with intraperitoneal radiocontrast admixed with the dialysis fluid. Peritoneal scintigraphy is also a reliable technique, as was the case in our patient. Tc-99m MAA, Tc-99m diethylene triamine pentaacetic acid (DTPA) and colloid can be used for diagnosis. In our patient, after suspecting pleuroperitoneal leakage,

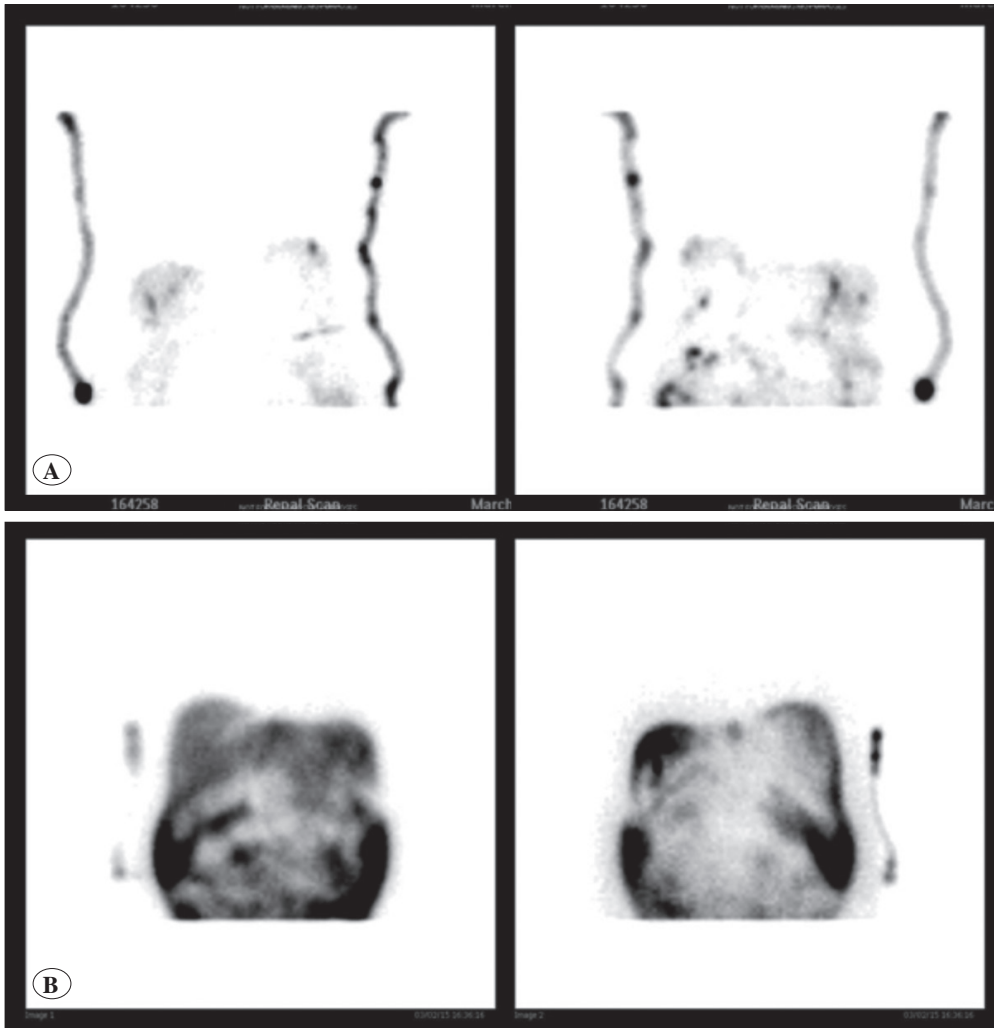


Figure 2: A) Early images Show no passing activity after 3 months later. B) Late (3rd hour) images again show no passing activity between peritoneum and pleura.

we investigated the biochemical properties of the serum and the pleural fluid that were obtained at the same time. The difference of more than 200 mg/dl in glucose concentrations between the samples was suggestive of pleuroperitoneal leakage. In order to confirm the connection between the pleural and peritoneal cavities we used the DTPA scintigraphy technique and verified the connection successfully (Figure 1A,B).

Temporary discontinuation of peritoneal dialysis and instead using hemodialysis is a preferred modality in the treatment of pleuroperitoneal leakage. This allows the peritoneum and related structures to rest and so ensure time for amelioration of the defects on the diaphragm (3). We switched to hemodialysis for three weeks. The signs and symptoms of pleural effusion completely disappeared. Even after turning back to CAPD with preoperative dialysate volume the condition did not recur. Three months after the time we had first shown the pleuroperitoneal leakage, we repeated the DTPA imaging and showed no activity passing through the diaphragm (Figure 2A,B). So this has been the first case report in the literature showing the connection and after some time showing the recovery.

In conclusion, pleuroperitoneal leakage can be seen anytime due to congenital and diaphragmatic defects in peritoneal dialysis patients. It can be detected with radionuclide peritoneography and the resolution can be controlled easily with the same imaging technique. The clinician can consider using this technique as a very useful option while investigating peritoneal dialysis patients with pleural effusion.

REFERENCES

1. Edwards SR, Unger AM: Acute hydrothorax—a new complication of peritoneal dialysis. JAMA 1967;199:853-855
2. Fletcher S, Turney JH, Brownjohn AM: Increased incidence of hydrothorax complicating peritoneal dialysis in patients with adult polycystic kidney disease. Nephrol Dial Transplant 1994;9:832-833
3. Chow KM, Szeto CC, Li PK: Management options for hydrothorax complicating peritoneal dialysis. Semin Dial 2003;16:389-394