

# Reversible Pseudo-RPGN and Severe Podocyte Injury Due to Intramuscular Deltamethrin Injection for Suicide Attempt: A Case Report

## *İntihar Amaçlı İntramişkiüler Deltamethrin Enjeksiyonuna Bağlı Gelişen Geri Dönüşümlü Psödo-RPGN ve Ciddi Podosit Hasarı: Bir Olgu Sunumu*

### ABSTRACT

Deltamethrin, an insecticide used in agriculture, may cause toxicity through inhalation, ingestion or parenteral administration. We described for the first time a pseudo-rapidly progressive glomerulonephritis due to intramuscular administration of deltamethrin with suicidal intent and emphasized predominant severe podocyte injury developed due to deltamethrin intoxication.

**KEY WORDS:** Deltamethrin, Podocyte injury, Pseudo-RPGN

### ÖZ

Tarım ilacı olarak kullanılan deltametrin solunum, sindirim veya parenteral yollarla zehirlenmeye neden olabilir. Biz ilk kez, intihar amaçlı intramüsküler deltametrin enjeksiyonu sonrasında gelişen bir psödo-RPGN olgusu sunduk ve deltametrin intoksikasyonu sonucu ön planda gelişen ciddi podosit hasarını vurguladık.

**ANAHTAR SÖZCÜKLER:** Deltamethrin, Podosit hasarı, Psödo-RPGN

### INTRODUCTION

Deltamethrin (DM) is a broad-spectrum insecticide mainly used to protect crops, fruit and vegetables from pests such as mites, ants, weevils and beetles throughout the world. DM is a member of one of the safest classes of pesticides: synthetic pyrethroids (1). DM is a neurotoxin for insects, but mammalian organisms are protected by poor dermal absorption and rapid metabolism to non-toxic metabolites. DM may cause toxicity through inhalation, ingestion or parenteral administration. Different pathophysiologic pathways including effects on voltage-sensitive sodium and chloride channels, effects on benzodiazepine receptors, and oxidative stress may be responsible for its toxic effects (2-4). Neurotoxicity, immunosuppression, allergy, hypertension, and hepatotoxicity due to deltamethrin have been reported in humans.

Deltamethrin-induced nephrotoxicity has been never reported in humans, yet. We described for the first time a pseudo-rapidly progressive glomerulonephritis due to intramuscular administration of deltamethrin with suicidal intent and emphasized predominant severe podocyte injury developed due to deltamethrin intoxication.

### CASE REPORT

A 46-year-old male patient, who had a diagnosis of schizophrenia, injected deltamethrin in his legs intramuscularly with suicidal intent. There was no history suggestive of co-ingestion of any other toxin or drug. Diffuse ecchymoses developed soon after the injection in his legs (Figure 1A). Bilateral 3+ edema was present. Laboratory: Serum creatinine: 1.68 mg/dl (serum creatinine was 0.8 mg/dl 2 months

**Simge BARDAK<sup>1</sup>**

**Kenan TUGUTALP<sup>1</sup>**

**Mert Koray ÖZCAN<sup>1</sup>**

**İclal GÜRSES<sup>2</sup>**

**Ebru BALLI<sup>3</sup>**

**Banu ÇOŞKUN YILMAZ<sup>3</sup>**

**Serap DEMİR<sup>1</sup>**

**Ahmet KIYKIM<sup>1</sup>**

1 Mersin University Faculty of Medicine, Department of Nephrology, Mersin, Turkey

2 Mersin University Faculty of Medicine, Department of Pathology, Mersin, Turkey

3 Mersin University Faculty of Medicine, Department of Histology and Embryology, Mersin, Turkey



Received : 12.12.2015

Accepted : 05.02.2016

Correspondence Address:

**Simge BARDAK**

Mersin Üniversitesi Tıp Fakültesi, Nefroloji Bilim Dalı, Mersin, Turkey

Phone : +90 324 241 00 00

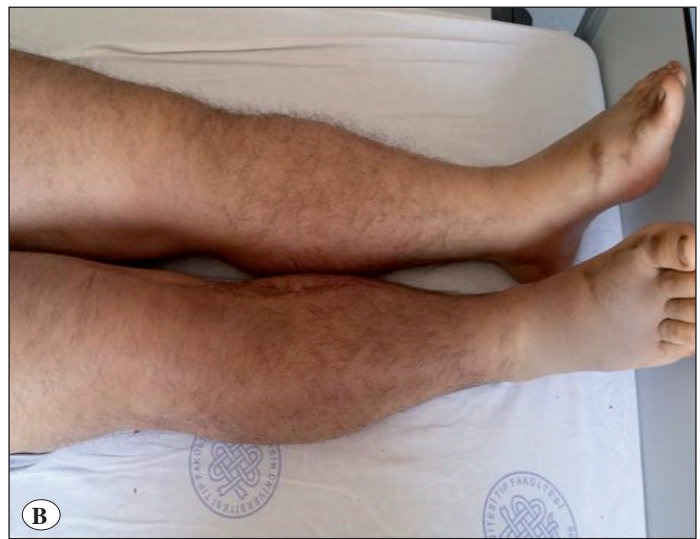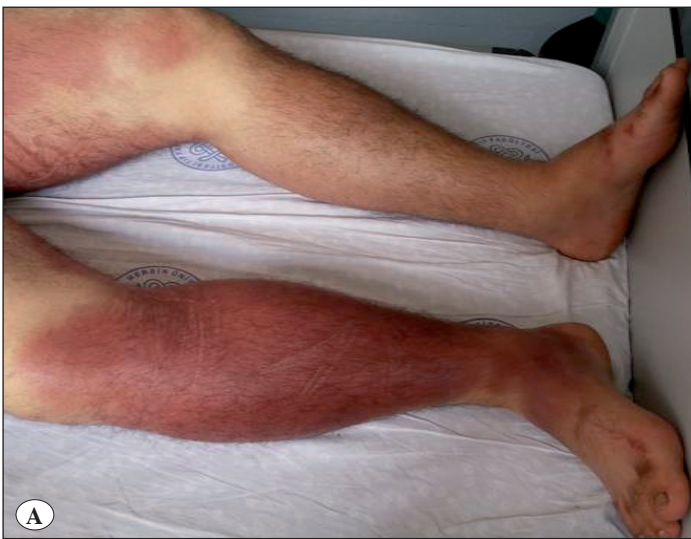E-mail : bardaksimge@gmail.com

ago), albumin: 2.2 gr/dl, pH: 7.36, HCO<sub>3</sub>: 12.2. Urine analysis: 27 erythrocytes, 24 leukocytes, protein 1+, glucose 1+. Urine culture: negative, 1.1 gr/d proteinuria. Doppler ultrasonography revealed normal renal arteries and normal kidney size. ANA 1/100+, dsDNA, ENA, CMV IgM, rubella IgM, Hbsag, antiHCV, antiHIV were negative. Thyroid function tests, C3, C4, IgA-G-M-E were normal. Serum creatinine was progressed and reached to 4.2 mg/dl. Renal biopsy was performed for differential diagnosis of RPGN. Crescent formation was not seen in histopathologic evaluation. Necrotic podocytes in Bowman space, erythrocyte casts in tubules and necrotic tubular cells were seen by light microscopy (Figure 2). Degenerative changes of podocytes, effacement of the foot processes of glomerular

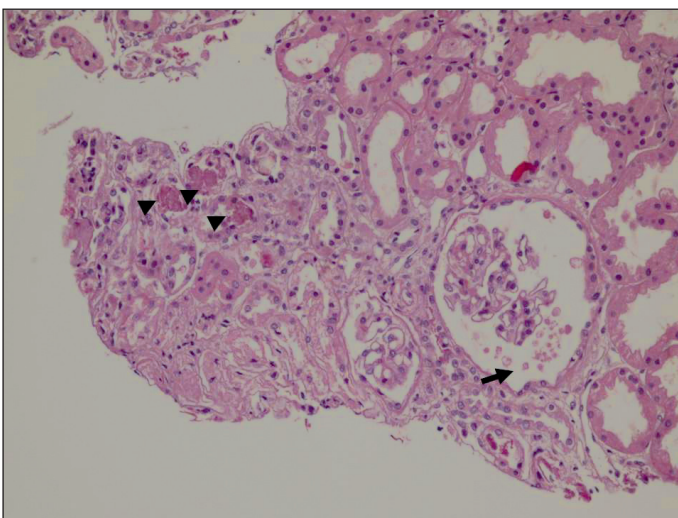
podocytes and degenerative cellular debris in bowman space were present by electron microscopy (Figure 3). Pseudo-RPGN was diagnosed. ANCA and anti-GBM antibodies were negative. Serum creatinine was decreased to 1.47 mg/dl spontaneously in the follow-up and also ecchymoses disappeared (Figure 1B).

## DISCUSSION

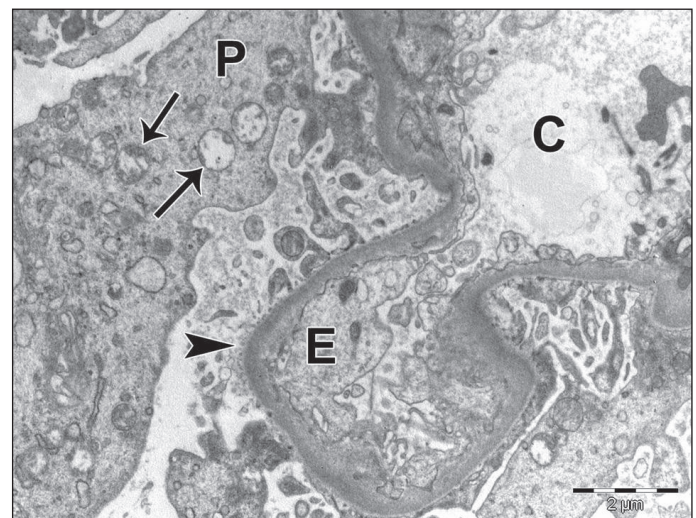
Clinical findings mimicking RPGN and severe podocyte injury were described after intramuscular administration of DM for suicide attempt in our case. Pyrethroids are used widely as insecticides both in the home and commercially, and in medicine for the topical treatment of scabies. DM is metabolized mostly in liver and excreted via kidneys (5). Previous surveys have



**Figure 1:** A) Diffuse ecchymoses developed after the injection of deltamethrin into his legs, B) Ecchymoses disappeared at follow-up.



**Figure 2:** Erythrocyte casts in tubule (arrow heads) and necrotic podocytes in Bowman space (Arrow) (x200).



**Figure 3:** Disruption of organelles in podocytes and diffuse loss of foot processes of podocytes. Podocyte (P), mitochondrial injury (arrow), loss of foot processes (arrow head), capillary (C), endothelial cell (E). (x10.000).

reported that 80–90% of American households use pesticides and that 80% or more of personal exposures come from indoor sources (6).

Although the acute toxicity of DM in adults has been well characterized (1), the potential toxicity of pyrethroids is not well understood. Despite their extensive worldwide use, there are relatively few reports of human pyrethroid poisoning (1).

Pyrethroids are known for their neurotoxicity in vertebrates and humans. The main adverse effect of dermal exposure is paresthesia. Systemic effects occur 4-48 hours after exposure. Pyrethroids generally produce salivation, hyperexcitability, choreoathetosis, and seizures. Dizziness, headache and fatigue are common, whereas palpitations, chest discomfort, and blurred vision may occur less frequent. Coma and convulsions are the principal life-threatening features (1). It has been reported in one large series that gastrointestinal symptoms and signs were the most common (73%), whereas central nervous system involvement which included confusion, seizures, and coma was present in 33% of patients with pyrethroid toxicity (7). Mild renal dysfunction was reported in 10% of patients in same series, but histopathological analysis had not been done (7). Cha et al. showed that atypical presentations including respiratory failure (17%), hypotension (10%), and acute kidney injury (10%) were seen in 39% of the patients (8). Immunosuppression, allergy, cardiac conduction disturbances (9), hypertension, and hepatotoxicity due to deltamethrin were reported (5). Death is very rare due to pyrethroids' toxicity (1).

Intentional pyrethroid poisoning often occurs due to oral consumption in a dose dependent manner. Intramuscular injection of DM and its results have never been reported before this report. Injected dose was unknown in our case. Different pathophysiologic pathways including effects on voltage-sensitive sodium and chloride channels, effects on benzodiazepine receptors, and oxidative stress may be responsible for pyrethroids' toxic effects (2-4). Pyrethroids modify the gating characteristics of voltage-sensitive sodium channels to delay their closure (1,2). In addition, oxidative stress may contribute to the DM intoxication (3). DM might cause renal tubular degeneration and was associated with intraluminal casts, cell debris, and leucocyte infiltration in experimental models (3). The extensive histopathological investigation of pyrethroids nephrotoxicity has not been reported in humans, yet. Renal histopathological evaluation of our case revealed that podocytes are the most seriously affected part of nephron by parenteral DM intoxication. Whether this is a class effect is not known. Electron microscopy may be important in the diagnosis of effacement of foot processes of glomerular podocytes and degenerative cellular debris.

There are no antidotes, and the treatment consists of supportive care. In time, DM is metabolized, with a rapid loss of toxicity. Most patients recover within 6 days, although there were seven fatalities among 573 cases in one series (1). In our case, renal replacement therapy was not performed and the patient recovered spontaneously within 10 days. World Health Organization published a report about specifications and evaluations for Deltamethrin in October 2015 (10).

In conclusion, intramuscular administration of DM may cause pseudo-RPGN and podocytes are the most seriously affected part of nephron by parenteral DM intoxication.

## REFERENCES

1. Bradberry SM, Cage SA, Proudfoot AT, Vale JA: Poisoning due to pyrethroids. *Toxicol Rev* 2005;24:93-106
2. Soderlund DM, Clark JM, Sheets LP, Mullin LS, Piccirillo VJ, Sargent D, Stevens JT, Weiner ML: Mechanisms of pyrethroid neurotoxicity: Implications for cumulative risk assessment. *Toxicology* 2002;171:3-59
3. Sharma P, Singh R, Jan M: Dose-dependent effect of deltamethrin in testis, liver, and kidney of wistar rats. *Toxicol Int* 2014;21:131-139
4. Aydin M, Yildiz A, İbiloğlu I, Ekinci A, Ülger BV, Yuksel M, Bilik MZ, Ozaydogdu N, Ekinci C, Yazgan UC: The protective role of glutamine against acute induced toxicity in rats. *Toxicol Mech Methods* 2015;25:296-301
5. Gündüz E, Ülger BV, İbiloğlu İ, Ekinci A, Dursun R, Zengin Y, İçer M, Uslukaya Ö, Ekinci C, Güloğlu C: Glutamine provides effective protection against deltamethrin-induced acute hepatotoxicity in rats but not against nephrotoxicity. *Med Sci Monit* 2015;21:1107-1114
6. Berkowitz GS, Obel J, Deych E, Lapinski R, Godbold J, Liu Z, Landrigan PJ, Wolff MS: Exposure to indoor pesticides during pregnancy in a multiethnic, urban cohort. *Environ Health Perspect* 2003;111:79-84
7. Yang PY, Lin JL, Hall AH, Tsao TC, Chern MS: Acute ingestion poisoning with insecticide formulations containing the pyrethroid permethrin, xylene, and surfactant: A review of 48 cases. *J Toxicol Clin Toxicol* 2002;40:107-113
8. Cha YS, Kim H, Cho NH, Jung WJ, Kim YW, Kim TH, Kim OH, Cha KC, Lee KH, Hwang SO, Nelson LS: Pyrethroid poisoning: Features and predictors of atypical presentations. *Emerg Med J* 2014;31:899-903
9. Bhaskar EM, Moorthy S, Ganeshwala G, Abraham G: Cardiac conduction disturbance due to prallethrin (pyrethroid) poisoning. *J Med Toxicol* 2010;6:27-30
10. World Health Organization: WHO specifications and evaluations for public health pesticides. 2015 Oct. Accessed 10.12.2015. Available from: [http://www.who.int/whopes/quality/Deltamethrin\\_PBO\\_incorporated\\_LN\\_spec\\_and\\_eval\\_WHO\\_October\\_2015.pdf](http://www.who.int/whopes/quality/Deltamethrin_PBO_incorporated_LN_spec_and_eval_WHO_October_2015.pdf)