

# Colchicine-and Clarithromycin-Induced Rhabdomyolysis in a Hemodialysis Patient with Familial Mediterranean Fever

Amir Hossein Abedi<sup>1</sup>, Eray Eroğlu<sup>2</sup> , İsmail Koçyiğit<sup>2</sup> , Aydın Ünal<sup>2</sup>, Murat Hayri Sipahioğlu<sup>2</sup>, Bülent Tokgöz<sup>2</sup> , Oktay Oymak<sup>2</sup>

<sup>1</sup>Department of Internal Diseases, Erciyes University School of Medicine, Kayseri, Türkiye

<sup>2</sup>Department of Nephrology, Erciyes University School of Medicine, Kayseri, Türkiye

81

## Abstract

Familial Mediterranean fever (FMF) is an autosomal recessive hereditary disease characterized by recurrent attacks of fever, usually accompanied by sterile polyserositis. Although colchicine is the main medical treatment option for FMF, potential adverse effects and drug interactions should be considered during the follow-up of these patients. Herein, we presented a case of a hemodialysis patient with FMF, who developed rhabdomyolysis due to concomitant use of colchicine and clarithromycin for pneumonia treatment.

**Keywords:** Colchicine, rhabdomyolysis, kidney failure

**Corresponding Author:** Eray Eroğlu ✉ drerayeroglu@hotmail.com

**Received:** 13.07.2017 **Accepted:** 15.08.2017

**Cite this article as:** Abedi AH, Eroğlu E, Koçyiğit İ, Ünaş A, Sipahioğlu MH, Tokgöz B, et al. Colchicine-and Clarithromycin-Induced Rhabdomyolysis in a Hemodialysis Patient with Familial Mediterranean Fever. Turk J Nephrol 2019; 28(1): 81-3.

## INTRODUCTION

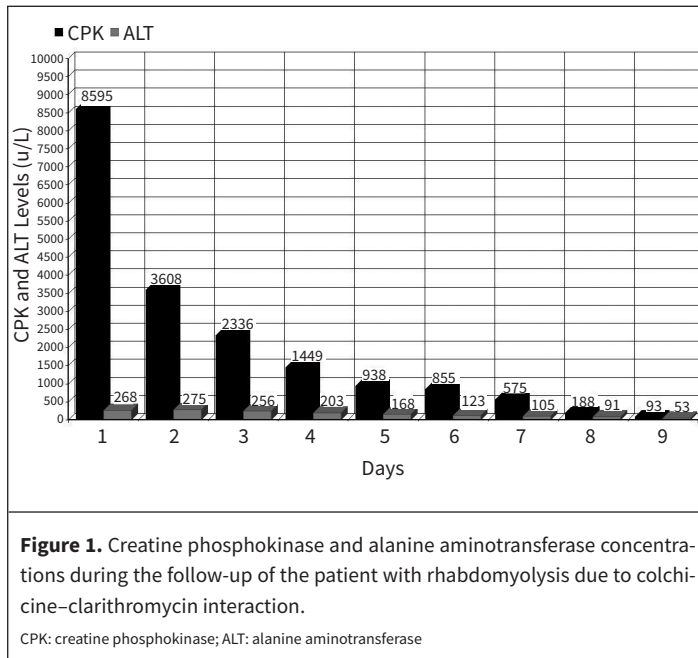
Familial Mediterranean fever (FMF) is the most common monogenic autoinflammatory disease, affecting mainly the ethnic groups originating from the Mediterranean basin. FMF is caused by mutations in the MEditerranean FeVer (MEFV) gene coding for pyrin, which is a component of the inflammasome functioning in inflammatory response. Clinical presentation usually consists of recurrent fever attacks and serosal inflammation. End-stage renal disease due to secondary AA type amyloidosis is the major cause of morbidity and mortality in patients with FMF (1). Colchicine is an anti-inflammatory drug, largely used in the treatment of patients with FMF. It affects the motility of neutrophils, which is crucial for their extravasation in response to inflammatory stimuli. Colchicine is metabolized via the enzyme CYP3A4 and is transported by P-glycoprotein. At therapeutic doses, it is well tolerated, except for moderate gastrointestinal disturbances (2). Long-term administration of colchicine reduces FMF attacks and prevents amyloidosis development (3). Rhabdo-

myolysis is one of the important colchicine adverse effects that may occur at toxic doses due to drug interactions, and kidney or liver failure (4). We describe the case of rhabdomyolysis in a hemodialysis patient with FMF under colchicine treatment after clarithromycin co-administration for pneumonia.

## CASE PRESENTATION

A 55-year-old male patient with FMF who had been on hemodialysis therapy for 7 years was admitted to our hospital for generalized myalgia and weakness. He had a known history of chronic kidney disease of unknown etiology, hypertension, chronic obstructive pulmonary disease, FMF, and ankylosing spondylitis. Kidney biopsy was not performed due to fibrotic kidneys on the initiation of renal replacement therapy 7 years ago. His medication included pregabalin 75 mg once daily (due to neuropathic pain that had lasted for a year), calcium acetate 1000 mg twice daily, etanercept 25 mg twice weekly, and colchicine 0.5 mg once daily. The patient had recently been diagnosed with pneumonia and was





prescribed clarithromycin 500 mg once daily 10 days before. Etanercept was discontinued due to infection.

The patient was hemodynamically stable and afebrile. Cardiovascular and abdominal examinations were unremarkable. The pulmonary examination revealed basilar wheezes and ronchi. The neurological examination revealed that the upper and lower extremities had a tender muscle structure with muscle weakness in the lower extremities (Grade 3/5). Deep tendon reflexes were diminished on the upper extremities and were absent on the lower extremities.

Laboratory studies revealed the following findings: hemoglobin 11.4 g/dL (14-18 g/dL), leucocyte count  $4.97 \times 10^6/L$  ( $4.8-10.7 \times 10^6/L$ ), platelet count  $132 \times 10^9/L$  ( $130-400 \times 10^9/L$ ), blood urea nitrogen was 56.0 mg/dL (6-20 mg/dL), creatinine 8.79 mg/dL (0.7-1.2 mg/dL), aspartate aminotransferase 603 u/L (0-40 u/L), alanine aminotransferase 268 u/L (0-41 u/L), creatine phosphokinase (CPK) 8595 u/L (39-308 u/L), creatine kinase-MB 198 U/L ( $\leq 25$  u/L), and high-sensitive cardiac troponin T 0.194 ng/mL (0-0.014 ng/mL). The urine analysis could not be performed because the patient was anuric. The serum thyroid stimulating hormone level was normal. Hepatitis testing was positive for Anti-HCV. The quantitative HCV RNA test was negative. Hepatobiliary ultrasound was normal. Investigations ruled out an infectious process, in particular serologies for HIV, brucella, CMV, and EBV. Electroneuromyography revealed significant sensorimotor neuropathy, bilaterally on the lower extremities. The patient was diagnosed with colchicine-induced rhabdomyolysis caused by clarithromycin interaction. Colchicine was discontinued. Patient was followed by routine dialysis and subsequently recovered without treatment in 2 weeks. During the follow-up, the patient's transaminases and CPK returned to normal levels (Figure 1). Written informed consent was obtained from patient who participated in this case.

## DISCUSSION

After the development of end-stage renal disease due to amyloidosis secondary to FMF, most patients still need to continue colchicine treatment to prevent FMF attacks and to halt the progression of the amyloid deposition in the tissues (2). However, a daily colchicine dose should be reduced in patients with renal insufficiency, and they should also be carefully followed-up in terms of potential drug interactions and colchicine toxicity (5).

Colchicine is mainly metabolized in the liver by the CYP3A4 enzyme and is eliminated by P-glycoprotein through bile excretion. In addition, 10%-20% of the colchicine metabolites are eliminated by kidneys (2, 3). As the inhibition of both the CYP3A4 enzyme and P-glycoprotein, such as cyclosporine or clarithromycin, can increase colchicine dose excessively due to dual blockade and adverse effects are seen more commonly with drug–drug pharmacokinetic interactions (6). Rhabdomyolysis is one of the important adverse effects of colchicine toxicity, and it typically presents with fever, fatigue, and muscle weakness and tenderness (7). Colchicine-induced rhabdomyolysis has also been observed in patients with preexisting renal or liver failure (8). In addition, colchicine-induced rhabdomyolysis has been well documented in several case reports, specifically with a concomitant use of fibrate, gemfibrozil, statins, cyclosporine, and clarithromycin (9). Thus, Hung et al. (10) retrospectively analyzed 116 patients who were prescribed clarithromycin and colchicine during the same clinical admission in terms of toxicity. They concluded that clarithromycin increased the risk of fatal colchicine toxicity, especially for patients with renal insufficiency and presenting with severe pancytopenia. Cessation of colchicine and clarithromycin resulted in recovery in many patients. Kato et al. (11) reported a case about pregabalin- and azithromycin-induced rhabdomyolysis with purpura. In that case, the patient was also using fenofibrate, and thus, it is possible that the drug interaction was between fenofibrate and azithromycin. It was reported that azithromycin increases the bioavailability of ivermectin, which is metabolized by CYP3A4. This report is suggestive of a drug interaction between azithromycin and statins. Pregabalin does not inhibit the hepatic metabolism or cytochrome P450 metabolism. It is not known whether the combination of pregabalin and azithromycin increases the risk of rhabdomyolysis. Moreover, rhabdomyolysis associated with azithromycin or pregabalin monotherapy is very rare. However, it has been reported that the pregabalin and statin interaction may induce rhabdomyolysis (12). In our case, the patient recovered with the cessation of colchicine and clarithromycin administration. In addition, neither pancytopenia nor purpura has been observed during the follow-up. The patient continued pregabalin medication due to neuropathic pain. Pregabalin-induced rhabdomyolysis may be found in the differential diagnosis of patient if no clinical improvement has been achieved.

However, colchicine is an important drug in the treatment of FMF; thus, physicians should be alert prescribing medications to patients with FMF, especially if they suffer from renal dysfunction, since the results could be fatal.

**Informed Consent:** Written informed consent was obtained from patient who participated in this case.

**Peer-review:** Externally peer-reviewed.

**Author Contributions:** Concept – O.O.; Design – E.E.; Supervision – İ.K.; Resources – A.H.A.; Materials – E.E., M.H.S.; Data Collection and/or Processing – E.E., A.H.A.; Analysis and/or Interpretation – B.T., İ.K.; Literature Search – E.E.; Writing Manuscript – E.E., A.H.A.; Critical Review – İ.K., A.Ü.

**Conflict of Interest:** The authors have no conflicts of interest to declare.

**Financial Disclosure:** The authors declared that this study has received no financial support.

## REFERENCES

1. Ben-Chetrit E, Touitou I. Familial mediterranean Fever in the world. *Arthritis Rheum* 2009; 61: 1447-53. [\[CrossRef\]](#)
2. Cocco G, Chu DC, Pandolfi S. Colchicine in clinical medicine. A guide for internists. *Eur J Intern Med* 2010; 21: 503-8. [\[CrossRef\]](#)
3. Zemer D, Pras M, Sohar E, Modan M, Cabili S, Gafni J. Colchicine in the prevention and treatment of the amyloidosis of familial Mediterranean fever. *N Engl J Med* 1986; 314: 1001-5. [\[CrossRef\]](#)
4. Tateishi T, Soucek P, Caraco Y, Guengerich FP, Wood AJ. Colchicine biotransformation by human liver microsomes. Identification of CYP3A4 as the major isoform responsible for colchicine demethylation. *Biochem Pharmacol* 1997; 53: 111-6. [\[CrossRef\]](#)
5. Çelebi ZK, Akturk S, Oktay EI, Duman N, Keven K. Colchicine-induced rhabdomyolysis following a concomitant use of clarithromycin in a haemodialysis patient with familial Mediterranean fever. *Clin Kidney J* 2013; 6: 665-6. [\[CrossRef\]](#)
6. Rollot F, Pajot O, Chauvelot-Moachon L, Nazal EM, Kélaïdi C, Blanche P. Acute colchicine intoxication during clarithromycin administration. *Ann Pharmacother* 2004; 38: 2074-7. [\[CrossRef\]](#)
7. van der Velden W, Huussen J, Ter Laak H, de Sévaux R. Colchicine-induced neuromyopathy in a patient with chronic renal failure: the role of clarithromycin. *Neth J Med* 2008; 66: 204-6.
8. Wilbur K, Makowsky M. Colchicine myotoxicity: case reports and literature review. *Pharmacotherapy* 2004; 24: 1784-92. [\[CrossRef\]](#)
9. Cohen O, Locketz G, Hershko AY, Gorshtein A, Levy Y. Colchicine-clarithromycin-induced rhabdomyolysis in Familial Mediterranean Fever patients under treatment for *Helicobacter pylori*. *Rheumatol Int* 2015; 35: 1937-41. [\[CrossRef\]](#)
10. Hung IF, Wu AK, Cheng VC, Tang BS, To KW, Yeung CK, et al. Fatal interaction between clarithromycin and colchicine in patients with renal insufficiency: a retrospective study. *Clin Infect Dis* 2005; 41: 291-300. [\[CrossRef\]](#)
11. Kato K, Iwasaki Y, Onodera K, Higuchi M, Kato K, Kato Y, et al. Pregabalin- and azithromycin-induced rhabdomyolysis with purpura: An unrecognized interaction: A case report. *Int J Surg Case Rep* 2016; 26: 221-3. [\[CrossRef\]](#)
12. Kaufman MB, Choy M. Pregabalin and simvastatin: first report of a case of rhabdomyolysis. *PT* 2012; 37: 579-95.