

# A Rare Skin Lesion in Kidney Transplant Recipients: Pyogenic Granuloma

Gülsüm Akkuş<sup>1</sup> , Feyza Nur Sarışık<sup>1</sup> , Alper Ural<sup>2</sup> , Abdulkadir Yasir Bahar<sup>3</sup> , Ertuğrul Erken<sup>4</sup> ,  
Özkan Güngör<sup>4</sup> , Orçun Altunören<sup>4</sup> 

<sup>1</sup>Department of Internal Medicine, Kahramanmaraş Sütçü İmam University School of Medicine, Kahramanmaraş, Turkey

<sup>2</sup>Department of Plastic and Reconstructive Surgery, Kahramanmaraş Sütçü İmam University, Kahramanmaraş, Turkey

<sup>3</sup>Department of Pathology, Kahramanmaraş Sütçü İmam University School of Medicine, Kahramanmaraş, Turkey

<sup>4</sup>Department of Nephrology, Kahramanmaraş Sütçü İmam University School of Medicine, Kahramanmaraş, Turkey

177

## Abstract

Renal transplant recipients have an increased risk of malignancy, especially skin cancers. Therefore, skin lesions in transplant patients should not be ignored. Pyogenic granuloma (PG) is a benign hyperplastic lesion of the connective tissue that manifests ulcerous and hemorrhagic masses and is therefore confused with malignancies. Repeated minor traumas, vascular wall infections, and poor oral hygiene play a role in the development of these lesions. In the literature, only three case reports of patients who have had a kidney transplant and a PG have been reported. In this article, we present two cases of renal transplant in which the patients developed a PG, because they are rarely seen and can be confused with skin malignancies in patients who have had a kidney transplant.

**Keywords:** Kidney transplantation, pyogenic granuloma, lobular capillary hemangioma

**Corresponding Author:** Orçun Altunören ✉ [orcunaltunoren@hotmail.com](mailto:orcunaltunoren@hotmail.com)

**Received:** 19.02.2019 **Accepted:** 30.04.2019

**Cite this article as:** Akkuş G, Sarışık FN, Ural A, Bahar AY, Erken E, Güngör Ö, et al. A Rare Skin Lesion in Kidney Transplant Recipients: Pyogenic Granuloma. *Turk J Nephrol* 2020; 29(2): 177-80.

## INTRODUCTION

Kidney transplantation is the most effective treatment for end-stage renal failure. However, immunosuppressive drugs used after transplantation puts patients who have had a kidney transplant at a higher risk for developing malignancy than the general population. The most common malignancies are skin cancers; lymphomas; and colon, breast, prostate, lung, bladder, and vulvar cancers. Skin cancers, with a prevalence of up to 40%, are the most common type of cancer in this patient population, and the risk of skin cancer increases as the time after transplantation increases. The Kidney Disease Improving Global Outcomes (KDIGO) guide recommends that patients who have had a kidney transplant perform skin self-examinations once a month and are examined by a specialist in skin cancer once a year.

Pyogenic granuloma (PG) is a hyperplastic benign skin lesion which is often confused with malignancy because of its fast growing and bleeding appearance and causes serious anxiety in both patient and physician. Because it

is rarely seen in kidney transplant patients and in order to increase the awareness of nephrologists in terms of skin lesions in the follow-up of kidney transplant patients, in this article, we presented two cases in which the patients were diagnosed with PG after kidney transplant.

## CASE PRESENTATION

### Case 1

A 54-year-old male patient who underwent cadaveric kidney transplantation 9 years ago owing to hypertension-associated end-stage renal failure presented to the outpatient clinic with a complaint of two red swellings that appeared on the back of his right hand in the past 3 months. On physical examination, two mass lesions with a 3-cm diameter ulcer and bleeding were detected lateral to the dorsal side of the right hand (Figure 1). No abnormalities were found during the examination of other systems. In laboratory tests, fasting blood glucose was 90 mg/dL, Blood Urea Nitrogen (BUN) 30 mg/dL, Cr 1.9 mg/dL, Na<sup>+</sup> 141 mEq/L, K<sup>+</sup> 3.8 mEq/L, Ca<sup>++</sup> 9.4 mg/dL,



This work is licensed under a Creative Commons Attribution 4.0 International License.

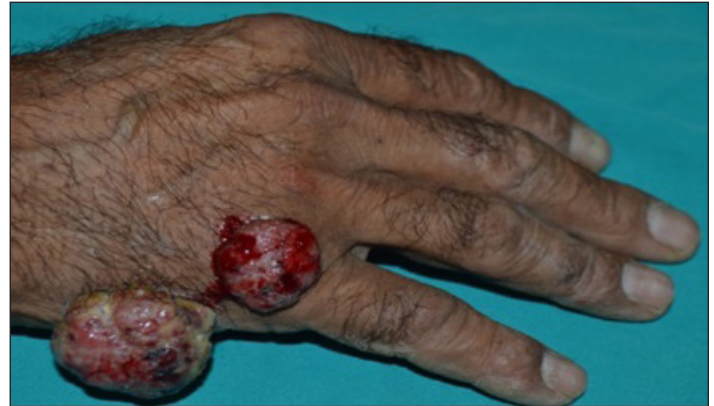phosphorus 3.7 mg/dL, albumin 4.5 g/dL, uric acid 6.3 mg/dL, and CRP 3.2 mg/L. Blood counts showed white blood cell count was 9,000/ $\mu$ L, Hb 14 g/dL, and platelet count 240,000/ $\mu$ L. Urinalysis showed urine density 1,016, protein trace, and erythrocyte was not detected. The patient had 490 mg/day proteinuria, based on the spot urine protein/creatinine ratio. The patient was using mycophenolate mofetil 1,000 mg/day, tacrolimus 1.5 mg/day, prednisolone 5 mg/day, and diltiazem 2 $\times$ 120 mg. The tacrolimus level was 5.23 ng/mL. Retrospectively, the results of the patient showed that the serum creatinine had a course between 1.6 and 2.2 mg/dL. The patient did not have any history of trauma on his hand. The patient consulted with dermatology and plastic surgery, and because the lesions on his hand did not respond to topical antibiotic treatment, they were excised by plastic surgery, with preliminary diagnoses of PG, hemangioma, fibroma, angiosarcoma, deep mycosis, and giant cell granuloma. The excised nodular masses were sent to the pathology department, and the pathological diagnosis of the preparations examined was reported as lobular capillary hemangioma (PG) (Figures 2 and 3).

## Case 2

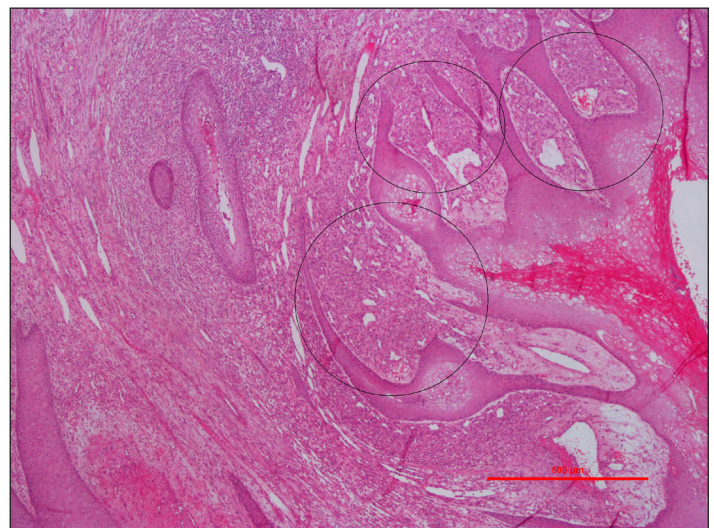
A 47-year-old male patient who underwent cadaveric kidney transplantation 8 years ago because of end-stage renal failure associated with hypertension presented to the outpatient clinic with an increasingly enlarged lesion on the right wrist. On physical examination, all systems were normal and a granular mass of 4 $\times$ 4 cm was detected on the dorsoradial right wrist. At the time of admission, BUN was 20.9 mg/dL, Cr 0.99 mg/dL, Na 141 mEq/L, K 4.4 mEq/L, Ca 9.4 mg/dL, phosphorus 3 mg/dL, albumin 3.9 g/dL, uric acid 6.6 mg/dL, and CRP 17.3 mg/L. Blood counts showed white blood cell count was 11,700/ $\mu$ L, Hb 9.6 g/dL, and platelets 243,000/ $\mu$ L. A full urine examination showed a urine density of 1,024, and protein and erythrocytes were not detected. The patient was using mycophenolate mofetil 1,000 mg/day, sirolimus 1 mg/day, and prednisolone 5 mg/day. Sirolimus level was 1.5  $\mu$ g/L. The patient did not have any history of trauma to his hand. On consultation with the dermatology department, a biopsy was performed as the lesion on the hand of the patient did not respond to topical antibiotics. Plastic surgery department consulted with the patient when his pathology report showed the lesion as a PG. Total excision of the lesion

## Main Points

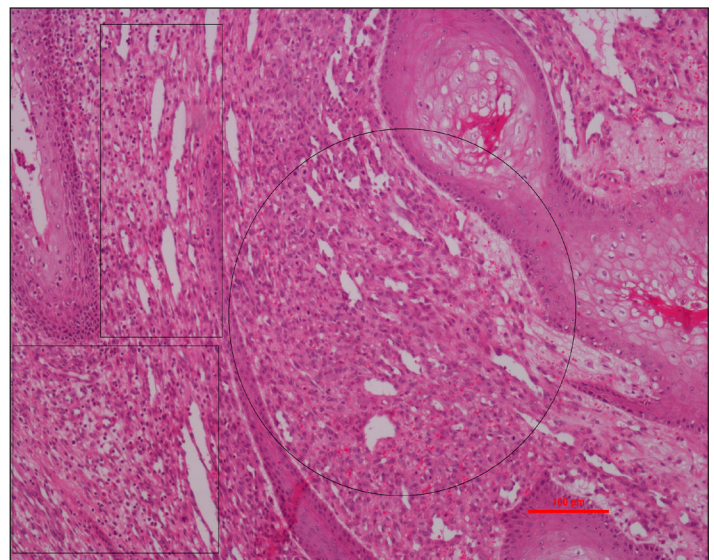
- Pyogenic granuloma is a fast growing benign skin lesion which rarely seen in kidney transplant recipients. Despite its benign character it has quite malignant and scary appearance.
- Kidney transplant patients are at risk for the development of various malignancies, mainly skin cancers.
- Physicians following kidney transplant patients should pay special attention to skin examination of the patients and advise them to perform their own skin examinations every month.



**Figure 1.** Two mass lesions with ulcer and bleeding on the back of the right hand.



**Figure 2.** Capillary proliferation present in the papillary dermis as lobules (areas in the circle), whereas hyperkeratotic and acanthotic epidermis are observed on the surface (hematoxylin-eosin, 4 $\times$  objective).



**Figure 3.** The lesion (circled) is accompanied by chronic inflammation and secondary inflammatory granulation tissue (areas within the rectangle) (hematoxylin eosin 10 $\times$  objective).

**Table 1.** Demographical data of kidney transplant recipients with pyogenic granuloma in the literature

	Age/Gender	Time to appear after transplantation	A history of trauma	Localization	Recurrence	Immunosuppressive regimen
Le Meur et al. (1997)	53/Male	10 <sup>th</sup> week	Yes	Right thumb	In 6 week	Cyclosporine
Al Zayer et al. (2001)	14/Female	Unspecified	Unspecified	Gingiva	No	Cyclosporine Prednisolone
Baykan et al. (2013)	46/Male	18 <sup>th</sup> week	Unspecified	Right wrist	In 3 week	Tacrolimus MMF Prednisolone
Our data (Case 1)	54/Male	9 year	No	Right wrist	No	Tacrolimus MMF Prednisolone
Our data (Case 2)	47/Male	8 year	No	Right wrist	In 8 week	Sirolimus MMF Prednisolone

MMF: Mycophenolate mofetil

was performed by the plastic surgery clinic. The PG was treated with silver nitrate, and it developed again after 2 months on the edge of the wound of the excised area and in the inguinal region.

## DISCUSSION

PG (lobular capillary hemangioma) is a benign hyperplastic lesion originating from the connective tissue of soft tissues such as skin and mucous membranes (1, 2). This lesion, which can be seen at any age, is common in children, adolescents, and pregnant women (3, 4). It has been reported that 0.5% of all skin nodules in the pediatric age group are PGs (5, 6). PGs are seen most commonly in the third decade in the adult population (7). It has been reported that PGs are found in 2%-5% of pregnancies (8, 9). Although its pathogenesis is not precisely known, it is associated with minor trauma and chronic irritation (10, 11). In addition, there are studies showing that poor oral care, laser treatment, hormonal factors, organ transplantation, bone marrow transplantation, and the use of chemotherapy drugs (cyclosporine) play a role in its pathogenesis (1, 12-17). PG is often seen on the gingiva, lips, nasal mucosa, trunk, fingers, and toes (10, 18, 19). More rarely, it can also be seen in the larynx and trachea (20). Clinically, PG can grow from a few millimeters to 2-3 cm and then remain stable in size. They are often painless. They can have a flat surface, be pedunculated or broad-based, and be lobular or nodular. In addition, the surface of the lesion is often ulcerated and covered with a white-yellow colored fibrinous membrane. It can easily bleed, either spontaneously or because of irritation. It can be confused with malignancy because it is ulcerated and has a bleeding appearance. In the differential diagnosis, malignancies should definitely be considered (1, 2, 17, 19). Since kidney transplant patients are predisposed to the development of malignancy, especially skin-borne cancers, such skin lesions need to be evaluated appropriately. In the literature, there are only three case reports reporting PG in patients who have

had a kidney transplant (Table 1). Le Meur et al. (14) detected PG in one patient at the 10<sup>th</sup> week of transplantation, and the lesion recurred after excision, and it was treated by application of radiotherapy to the lesion. Al-Zayer et al. (15) reported a PG in the anterior maxillary gingiva with gingival hypertrophy in a 14-year-old male patient who had had a kidney transplant with cyclosporin. Baykan et al. (21) detected PG at the 10<sup>th</sup> week after kidney transplantation, and the lesion recurred 3 weeks after excision. Chemical cauterization was applied to the lesion, and the lesion did not recur. Although the main treatment approach for a PG is removal of predisposing factors and/or surgical excision, other treatment options such as cryotherapy, laser, electrocauterization, corticosteroid or ethanol injection into the lesion, and sclerotherapy are also used (22). PG tends to recur after excision, even if it has no potential for malignancy. Because the incidence of skin cancer is high patients who have undergone a kidney transplant, skin lesions should be well examined and, if necessary, relevant departments should be consulted. Cancers develop at different time intervals after kidney transplantation. Skin cancers are observed, on average, 69 months after transplantation. According to the KDIGO transplantation follow-up guide, to prevent skin cancer in patients who have had a kidney transplant, in the time intervals when ultraviolet light is the most intense, sunscreen avoidance, protective clothing, and creams should be used (23). Skin and lips should be self-examined by the patients or by one of their family members, and annual skin examination should be performed by experienced physicians. Acitretin (0.2-0.4 mg/kg/day) should be given if there is no contraindication in the patients with skin cancer (24).

## CONCLUSION

Because the frequency of skin cancer increases in patients who have undergone kidney transplantation, nephrologists should not ignore skin lesions in these patients and should evaluate them thoroughly.



**Informed Consent:** Written informed consent was received from the patients who participated in this case.

**Peer-review:** Externally peer-reviewed.

**Author Contributions:** Concept - O.A., G.A.; Resource - F.N.S., G.A.; Materials - A.U.; Data Collection and/or Processing - F.N.S., A.U.; Analysis and/or Interpretation - A.Y.B., E.E., Ö.G.; Literature Search - F.N.S., G.A.; Writing - G.A.; Critical Reviews - O.A., E.E., Ö.G., A.U., A.Y.B.

**Conflict of Interest:** The authors have no conflict of interest to declare.

**Financial Disclosure:** The authors declared that this case has received no financial support.

## REFERENCES

1. Angelopoulos AP. Pyogenic granuloma of the oral cavity: Statistical analysis of its clinical features. *J Oral Surg* 1971; 29: 840-7.
2. Kerr DA. Granuloma pyogenicum. *J Oral Surg* 1951; 4: 158-76. [\[Crossref\]](#)
3. Lin RL, Janniger CK. Pyogenic granuloma. *Cutis* 2004; 74: 229-33.
4. Yang C, Liu S. Treatment of giant pyogenic granuloma with the Nd/YAG holmium laser: A case report. *J Cosmet Laser Ther* 2013; 15: 225-7. [\[Crossref\]](#)
5. Scheinfeld NS. Pyogenic granuloma. *Skinmed* 2008; 7: 37-9. [\[Crossref\]](#)
6. Spinelli C, Di Giacomo M, Bertocchini A, Loggini B, Pingitore R. Multiple pyogenic granuloma of the penis in a four-year-old child: A case report. *Cases J* 2009; 2: 7831. [\[Crossref\]](#)
7. Patil P, Singla S, Mane R, Jagdeesh KS. Nasal lobular capillary hemangioma. *J Clin Imaging Sci* 2013; 3: 40. [\[Crossref\]](#)
8. Andrikopoulou M, Chatzistamou I, Gkilas H, Vilaras G, Sklavounou A. Assessment of angiogenic markers and female sex hormone receptors in pregnancy tumor of the gingiva. *J Oral Maxillofac Surg* 2013; 71: 1376-81. [\[Crossref\]](#)
9. Pagliai KA, Cohen BA. Pyogenic granuloma in children. *Pediatr Dermatol* 2004; 21: 10-3. [\[Crossref\]](#)
10. Requena L, Sanguenza OP. Cutaneous vascular proliferations. Part II. Hyperplasias and benign neoplasms. *J Am Acad Dermatol* 1997; 37: 887-919. [\[Crossref\]](#)
11. Chong K-M, Yeh T-C, Hwang J-L. Vulvar lobular capillary hemangioma (pyogenic granuloma). *Taiwanese J Obstet Gynecol* 2005; 44: 94-5. [\[Crossref\]](#)
12. Paradelo S, del Pozo J, Martínez W, Fernández-Jorge B, Rodríguez-Lozano J, Yebra-Pimentel T, et al. Pyogenic granuloma: Satellitosis after carbon dioxide laser vaporization resolved with an intense pulsed light system. *Dermatol Surg* 2007; 33: 104-8. [\[Crossref\]](#)
13. Freiman A, Bouganin N, O'Brien EA. Case reports: Mitozantrone-induced onycholysis associated with subungual abscesses, paronychia and pyogenic granuloma. *J Drugs Dermatol* 2005; 4: 490-2.
14. Le Meur Y, Bedane C, Clavère P, Peyronnet P, Leroux-Robert C. A proliferative vascular tumour of the skin in a kidney transplant recipient (recurrent pyogenic granuloma with satellitosis). *Nephrol Dial Transplant* 199; 12: 1271-3. [\[Crossref\]](#)
15. Al-Zayer M, da Fonseca M, Ship JA. Pyogenic granuloma in a renal transplant patient: Case report. *Spec Care Dentist* 2001; 21: 187-90. [\[Crossref\]](#)
16. Harris MN, Desai R, Chuang TY, Hood AF, Mirowski GW. Lobular capillary hemangiomas: An epidemiologic report, with emphasis on cutaneous lesions. *J Am Acad Dermatol* 2000; 42: 1012-6. [\[Crossref\]](#)
17. Neville BW, Damm DD, Allen CM, Chi AC. *Oral and Maxillofacial Pathology*. 2nd ed. Philadelphia: WB Saunders; 2002.
18. Arikan DC, Kiran G, Sayar H, Kostu B, Coskun A, Kiran H. Vulvar pyogenic granuloma in a postmenopausal woman: Case report and review of the literature. *Case Report Med* 2011: 201901. [\[Crossref\]](#)
19. Leyden JJ, Master GH. Oral cavity pyogenic granuloma. *Arch Dermatol* 1973; 108: 226-8. [\[Crossref\]](#)
20. Fechner RE, Cooper PH, Mills SE. Pyogenic granuloma of the larynx and trachea. A causal and pathologic misnomer for granulation tissue. *Arch Otolaryngol* 1981; 107: 30-2. [\[Crossref\]](#)
21. Baykan H, Ozyurt K, Ozkan F, Sen H, Altinoluk B, Ozkose M. Giant pyogenic granuloma in a renal transplant patient. *Eur J Plast Surg* 2013; 36: 271-4. [\[Crossref\]](#)
22. Lee J, Sinno H, Tahiri Y, Gilardino MS. Treatment options for cutaneous pyogenic granulomas: A review. *J Plast Reconstr Aesthet Surg* 2011; 64: 1216-20. [\[Crossref\]](#)
23. Kidney Disease: Improving Global Outcomes (KDIGO) Transplant Work Group. KDIGO clinical practice guideline for the care of kidney transplant recipients. *Am J Transplant* 2009; 9 Suppl 3: S1-S155. [\[Crossref\]](#)
24. Chen K, Craig JC, Shumack S. Oral retinoids for the prevention of skin cancers in solid organ transplant recipients: A systematic review of randomized controlled trials. *Br J Dermatol* 2005; 152: 518-23. [\[Crossref\]](#)