

The Protective Effect of Rutin Against Methotrexate-Induced Nephrotoxicity in Rats

Ali Kazım Tambağ¹ , Filiz Kazak¹ , Pınar Peker Akalın¹ , Tuncer Kutlu² 

¹Department of Biochemistry, Hatay Mustafa Kemal University Faculty of Veterinary Medicine, Hatay, Turkey

²Department of Pathology, Hatay Mustafa Kemal University Faculty of Veterinary Medicine, Hatay, Turkey

218

ABSTRACT

Objective: This study was purposed to investigate the possible protective effects of rutin on kidney tissue in a methotrexate-induced nephrotoxicity rat model.

Methods: Rats were randomly divided into 4 groups: control group, methotrexate (MTX, 20 mg/kg) group, rutin (RUT, 50 mg/kg/day) group, and methotrexate + rutin (MTX+RUT, 20 mg/kg + 50 mg/kg/day, respectively) group. Biochemical and histopathological analyzes were performed on kidney tissues of rats at the end of the study.

Results: It was determined that kidney tissue damage determined in the MTX group was decreased in the MTX + RUT group; there were no degenerative changes in the tubular epithelium of the MTX + RUT group, and only mild degenerative changes were observed rather than hydropic degeneration seen in MTX group.

Conclusion: This study suggests that rutin can be effective in preventing the toxic effects of methotrexate on the kidney.

Keywords: Methotrexate, nephrotoxicity, rutin

Corresponding author: Filiz Kazak ✉ filizkazak@mku.edu.tr

Received: November 3, 2020 **Accepted:** January 23, 2021

Cite this article as: Tambağ AK, Kazak F, Peker Akalın P, Kutlu T. The protective effect of rutin against methotrexate-induced nephrotoxicity in rats. *Turk J Nephrol.* 2021; 30(3): 218-223.

INTRODUCTION

Chemotherapeutic drugs are widely used against various types of cancer, and their clinical use causes side effects, including many organ toxicities. One of these drugs is methotrexate, a folate antagonist.¹ Methotrexate is a commonly prescribed antimetabolite drug used for various cancers and autoimmune diseases.^{2,3} Methotrexate is effective not only in treating cancers but also in various other disorders such as acute leukemia, psoriasis, and rheumatoid arthritis.⁴ Over 90% of methotrexate is excreted through the kidneys. Nephrotoxicity is one of the important complications of methotrexate treatment, which is considered to limit the use of methotrexate.^{2,5} Methotrexate causes Bowman capsule cavity enlargement, infiltration of lymphocytes, a decrease in size of glomeruli, an increase in blood cells, degeneration in kidney tubules.^{6,7,8} Although the etiology of renal dysfunction caused by methotrexate is believed to have a

direct toxic effect on kidney tubules, the pathogenesis of methotrexate-induced nephrotoxicity is not yet clear.^{6,9} Neutrophil infiltration and oxidative stress are shown as the cause of cellular damage in methotrexate-induced nephrotoxicity.^{8,10,11} Flavonoids are natural polyphenolic phytochemicals and are used in the prevention and treatment of many diseases such as cancer, cardiovascular diseases, neurodegenerative diseases, and diabetes. The protective effects of caffeic acid phenethyl ester,¹² carvacrol,¹³ gallic acid,¹⁴ propolis,⁶ and vitamin C¹⁵ have been shown in kidney damage caused by methotrexate in rats.

Rutin (3,3',4',5,7-pentahydroxyflavone-3-ramnogluco side), also called rutoside and quercetin-3-rutinoside, is a flavonoid found abundantly in plants such as passionflower, buckwheat, tea, and apple. Various pharmacological properties of rutin include antioxidant,



cytoprotective, vasoprotective, anticarcinogenic, neuroprotective, and cardioprotective effects.¹⁶ Some studies have shown that rutin has protective effects on kidneys in diabetic nephropathy,¹⁷ ischemia/reperfusion kidney damage,¹⁸ and drug-induced nephropathy.¹⁹ Rutin has been reported to prevent cisplatin-induced renal inflammation and apoptosis by reducing NF- κ B, TNF- α , and caspase-3 expression.²⁰ It has been reported that rutin (50 and 100 mg/kg) protected the kidney with its anti-oxidant, anti-apoptotic, and anti-inflammatory effects against kidney toxicity caused by HgCl₂ in rats.²¹

In the literature, there was no study investigating the possible protective/ameliorative effects of rutin in methotrexate-induced nephrotoxicity in rats. Therefore, the present study aimed to investigate the possible protective/ameliorative effects of rutin against the side effects of methotrexate, which is widely used especially for cancer treatment, on kidney tissue with biochemical analyzes, and histopathological examination in rats.

METHODS

Animals and Experimental Design

Male Wistar Albino rats, weighing approximately 250-300 g, were purchased from the Experimental Research Application and Research Center, Hatay Mustafa Kemal University. The study protocol was approved by the Local Ethical Committee of Experimental Animal Ethics of Hatay Mustafa Kemal University and was performed entirely according to ethical rules (Approval no: 2018/7-2, July 26, 2018). The animals were kept in polypropylene cages under standard temperature (25 \pm 2°C), laboratory humidity (45 \pm 5%), and 12 hours light/dark cycle conditions during the experiment. The rats were provided ad libitum food and water.

Adult male rats (n = 24) were randomly divided into 4 groups (6 rats for each group).

1. Control Group: The animals were administered orally distilled water for 15 days. Physiological saline (0.09% NaCl) was administered intraperitoneally (i.p.) on the eighth day of the study.
2. Methotrexate (MTX) Group: The animals were administered distilled water orally for 15 days. Methotrexate (Methotrexate,

Kocak Pharma, Turkey) was administered in a single dose of 20 mg/kg i.p. on the eighth day of the study (1).

3. Rutin (RUT) Group: Rutin (rutin hydrate, ABCR, Germany) was administered in a single dose of 50 mg/kg body weight orally, for 15 days (21). Physiological saline was administered i.p. on the eighth day of the study.
4. Methotrexate+rutin (MTX+RUT) Group: The animals were administered rutin for 15 days. Methotrexate was administered on the eighth day of the study.

Sample Collection and Preparation

At the 16th day of the study, anesthesia was produced by means of a cocktail prepared by using xylazine and ketamine hydrochloride. The rats were sacrificed, kidney tissues were obtained, and used for biochemical and histopathological examinations. One of the kidneys was placed in 10% neutral formalin solution for histopathological investigations while the other kidney of the rat was stored at -80 °C for biochemical analyses.

Preparation of Tissue Homogenates

The kidney tissues were homogenized in phosphate buffer (pH: 7.4) in 1:10 w/v with an ultrasonic homogenizer (Bandelin Electronic UW 2070, Germany) in cooled tubes with ice. Then the homogenates were centrifuged (18 000 rpm, +4°C, 10 min) to obtain tissue homogenate supernatants.

Biochemical Analyzes

Protein measurements were performed using Lowry's method²² spectrophotometrically (UV 2100 UV-VIS Recording Spectrophotometer Shimadzu, Japan). Levels of 8-hydroxy-2'-deoxyguanosine (8-OHdG) in the kidney tissue homogenates were detected with a commercial rat ELISA kit (SunRed, China) according to the manufacturer's instruction. The contents of these parameters were expressed as ng/g tissue. Total glutathione (tGSH) levels were estimated in the kidney tissue homogenates using a commercially available kit (GSH-420™ OxisResearch, USA). The contents of these parameters were expressed as μ mol/g protein. Glucose-6-phosphate dehydrogenase (G6PD) activities were determined by Beutler (1971)'s and glutathione peroxidase (GPx) activities were determined by Beutler (1975)'s methods spectrophotometrically.^{23,24} Results were expressed as U/g protein.

Histopathological Examination

The kidney tissues were fixed in a 10% buffered formalin. The fixated tissues were subjected to routine tissue follow-up. They were dehydrated in graded ethanol (50-100%) and were made transparent in xylol. The tissues were embedded in paraffin blocks. Cross-sections of 5 μ m thickness were obtained from each block by microtome. After the cross-sections, slides were left in a stove for 1 h, and the preparates were stained by hematoxylin-eosin (H&E). The preparates were observed under a light microscope (Olympus CX31, Germany). Later, the structural changes observed in the kidney tissue sections belonging

Main Points

- Methotrexate is widely used against various types of cancer, and its clinical use causes kidney damage.
- Studies have shown that rutin has a protective effect on nephrotoxicity. Rutin reduces the histopathological changes in the methotrexate-induced nephrotoxicity.
- Methotrexate treatment should be supported with rutin to avoid adverse effects.

to the control, and experiment groups were evaluated based on their positivity as none (–), mild (+), moderate (++), and severe (+++).^{14,25,26}

Statistical Analysis

The statistical analysis was performed by using a Statistical Package for the Social Sciences (SPSS) version 22.0 (IBM SPSS Corp.; Armonk, NY, USA). Prior to the significance tests, all data were evaluated by Shapiro–Wilk for normality from the parametric test hypotheses and by Levene test for the homogeneity of variances. Comparison of multiple groups was determined by analysis of variance (ANOVA) and post hoc Duncan test. The level of significance was accepted as $P < .05$. The values were expressed as mean \pm standard error (SE).

RESULTS

The 8-OHdG levels were found to be (Table 1) nearly the same levels as the control group (24.33 ± 1.35 ng/g tissue) in the MTX (25.30 ± 0.74 ng/g tissue), RUT (23.85 ± 0.86 ng/g tissue), and MTX+RUT (25.45 ± 1.14 ng/g tissue). The tGSH levels and G6PD activities did not change within the groups ($P > .05$). GPx activities decreased in the RUT group (333.73 ± 36.46 U/g protein, $P < .05$ Table 1) compared to the control group (441.78 ± 35.55 U/g protein, Table 1). Rutin administration decreased tissue G6PD and GPx concentration, but the decrease was not statistically significant in the MTX+RUT group compared with the MTX group (Table 1).

Macroscopically, the kidneys were slightly swollen, and their color was lighter than normal in the MTX group, while the kidneys were in normal structure in the other groups. Histopathological findings were summarized in Table 2. Histopathological evaluations revealed that the kidney tissues of the rats in the control and RUT groups were observed to have a normal histological appearance (Figure 1A). Small foci mononuclear inflammatory

Table 2. Histopathological Findings and their Scores in Kidney Tissue in Rats			
Groups	Mononuclear Cell Infiltration	Parenchymal Degeneration	Hydropic Degeneration
Control	–	–	–
MTX	+	++	++
RUT	–	–	–
MTX+RUT	–	+	+

The lesions in the whole area were scored for histopathological changes as –: no change (<5%), +: mild change (between 5 and 33%) and ++: moderate change (between 33 and 66%).

cell infiltration in the kidney tissue was observed in the MTX group (Table 2 and Figure 1B). Moreover, there were degenerative changes in the tubular epithelium, ranging from parenchyma to hydropic, in wide scope in the MTX group (Table 2 and Figure 1C). In the MTX+RUT group, especially only mild degenerative changes were determined rather than hydropic degeneration seen in the MTX group (Table 2 and Figure 1D). No lesions were noted in the glomeruli and vessels in all groups.

DISCUSSION

In the present study, the protective and ameliorative effects of rutin against acute methotrexate toxicity in rat kidneys were investigated. In the light of the literature review, it has been reported that administration of methotrexate to rats induces kidney damage and causes histopathological changes associated with the damage.^{1,3,27} Methotrexate can cause changes ranging from mild tubular degeneration to glomerulosclerosis.^{11,14,28} However, in the present study, no lesions were noted in the glomeruli and vessels. Mahmoud et al.²⁸ indicated that methotrexate caused various histopathological changes in kidney tissues, such as leukocyte infiltration, interstitial hemorrhage, and degenerative changes of tubular epithelial cells. Sakalli et al.¹¹ found renal degenerative changes of methotrexate including tubular distension, interstitial inflammation, perineal inflammation, glomerular congestion, glomerular degeneration, and parenchymal bleeding. In keeping with the previous research, the present study demonstrated that methotrexate caused macroscopic and microscopic changes in kidney tissues. The kidneys of the rats administered methotrexate were lighter in color and slightly swollen, macroscopically. Microscopically, degenerations from parenchyma to hydropic were found in the tubular epithelium in large areas of kidney tissues. Moreover, mononuclear inflammatory cell infiltration was observed in small foci.

8-OHdG is a potential biomarker for the early diagnosis of pathological conditions in the body.²⁹ It has been suggested that increased risk of kidney disease in individuals with type 1 diabetes is associated with high plasma 8-OHdG levels, and that 8-OHdG can be used to evaluate the progression of diabetic kidney disease.³⁰ In animal experimental, kidney damage

Table 1. Effects of Methotrexate and Rutin on some Biochemical Parameters in Rat Kidney

Groups	8-OHdG (ng/g tissue)	tGSH (μmol/g protein)	G6PD (U/g protein)	GPx (U/g protein)
Control	24.33 \pm 1.35	72.82 \pm 1.14	3.32 \pm 0.52	441.78 \pm 35.55 ^a
MTX	25.30 \pm 0.74	79.15 \pm 3.60	3.38 \pm 0.23	410.22 \pm 27.17 ^{ab}
RUT	23.85 \pm 0.86	73.61 \pm 2.97	2.51 \pm 0.43	333.73 \pm 36.46 ^b
MTX+RUT	25.45 \pm 1.14	75.61 \pm 2.44	3.14 \pm 0.22	375.22 \pm 34.15 ^{ab}

Values are expressed as mean \pm SE. Different superscripts (a, b, ab) in the same row indicate significant difference ($P < .05$) among groups. MTX, methotrexate; RUT, rutin; 8-OHdG, 8-hydroxy-2'-deoxyguanosine; tGSH, total glutathione; G6PD, glucose-6-phosphate dehydrogenase; GPx, glutathione peroxidase.

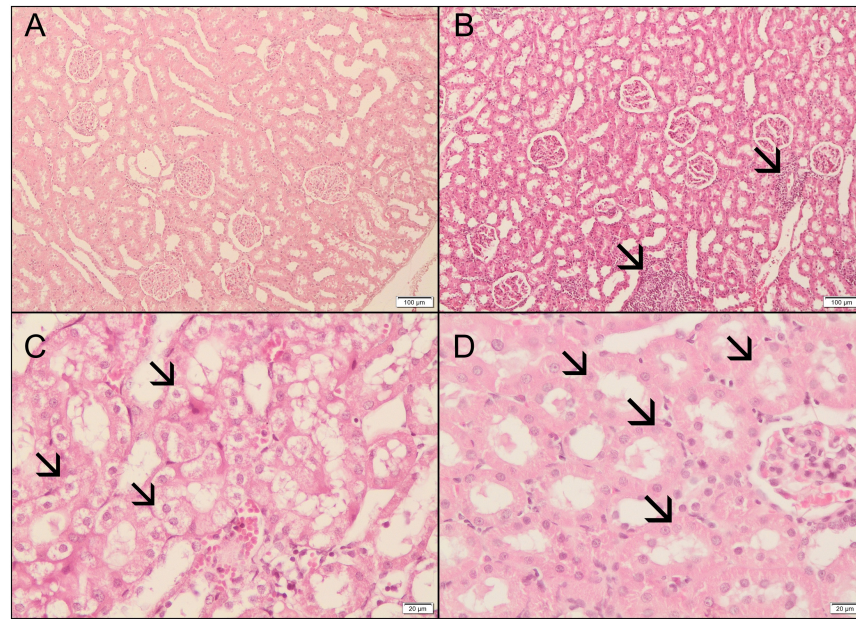


Figure 1. Effects of methotrexate and rutin on kidney tissue. (A) Control group was in normal histological appearance. (B) The sections showed extensive kidney damage, such as inflammatory cell infiltration (arrowheads) and (C) degeneration from parenchyma to hydropic, in tubular epithelium (arrowheads) in MTX group. (D) Parenchym degeneration (arrowheads) determined in MTX + RUT group (H&E, $\times 20$ and $\times 100$).

is created with various chemicals such as carbon tetrachloride and lead. It has been reported that the mentioned substances may cause an increase in the kidney 8-OHdG level.^{31,32} In cisplatin-induced acute renal failure, it has been revealed that cisplatin causes an increase in 8-OHdG expression in rat distal tubular cells.^{33,34} In the literature searches, no study was found to reveal the effects of methotrexate on kidney 8-OHdG. In the present study, neither methotrexate nor rutin affected kidney 8-OHdG levels in rats. It has been suggested that the significant reduction in GSH levels induced by methotrexate leads to a decrease in the effectiveness of the antioxidant defense system by sensitizing cells to reactive oxygen species.³⁵ It has been reported that methotrexate-decreased kidney reduced glutathione³⁶ and tGSH²⁸ levels. However, in this study, methotrexate did not change kidney tGSH levels. G6PD, the rate-limiting enzyme of the pentose phosphate pathway, is critical for normal cell growth and cell survival as it is the main source of the essential cellular reductant, NADPH.³⁷ According to literature reviews, changes in G6PD activity have been associated with acute kidney injury and hyperaldosteronism.³⁸⁻⁴⁰ Increased G6PD activity is reported to be related to all cancers, including kidney cancer.³⁷ Babiak et al.³⁵ reported that methotrexate inhibits G6PD and 6-phosphogluconate dehydrogenase activities in HeLa cells. To our knowledge, there was no study on the effects of methotrexate and rutin on kidney G6PD activity in rats. In the present study, it was determined that methotrexate and rutin did not alter kidney G6PD activity. GPx is a cellular enzymatic antioxidant, which reduces lipidic or nonlipidic hydroperoxides as well as hydrogen peroxide while oxidizing GSH.⁴¹ The effects of methotrexate (20 mg/kg, a

single dose, i.p.) on rat kidney GPx activity have been reported differently. Abd El-Twab et al.⁴² and Savran et al.¹⁵ reported that methotrexate decreased kidney GPx activity whereas Armagan et al.⁴³ reported unchanged kidney GPx activity in rats. In accordance with the findings of Armagan et al.⁴³, this study indicated that methotrexate administration did not change kidney GPx activity compared to the control group.

In the studies investigating the effects of rutin on the kidneys, it has been reported that the rutin did not show any negative effects on the glomerulus, tubule cells, and general structure of the kidney.^{20,44} Similar to previous studies, no pathological findings were found in the kidney tissues of rats after rutin administration. It has been reported that rutin did not alter kidney GSH levels.^{21,44,45} Similar to the researches, it was determined that rutin had no effect on kidney tGSH levels in the present study. Rutin administration did not alter kidney GPx activity at the doses of 50⁴⁴ and 100 mg/kg/day for 7 days,²¹ and besides, it increased GPx activity at the dose of 150 mg/kg/day for 14 days.⁴⁵ In this study, rutin (50 mg/kg/day for 15 days) caused a decrease in kidney GPx activity. These results may be attributed to the difference in the rutin dose and duration of administration. Rutin administration alone or in combination with methotrexate did not cause any alteration in kidney G6PD activity and 8-OHdG levels. Arjumand et al. (2011) reported that cisplatin induced damages (glomerular and peritubular congestion, increase in inflammatory cells, and necrosis) in the kidney, and administration of rutin plus cisplatin reduced this injury.²⁰ Similarly, in the present study, mononuclear cell infiltration determined in the MET group was

not observed in MTX + RUT group, and also hydropic degeneration was decreased.

CONCLUSION

The present study suggests that methotrexate caused damage in the kidney tissue, and rutin may have the potential to protect and ameliorate the kidney from methotrexate-induced nephrotoxicity. Along with methotrexate chemotherapy, rutin can be promising to alleviate the methotrexate-induced nephrotoxicity. Thus, it is recommended to investigate the possible protective and curative effects of rutin on methotrexate-induced nephrotoxicity at different doses and time intervals by further studies.

Ethics Committee Approval: Ethics committee approval was received from the Ethical Committee of Experimental Animal Ethics of Hatay Mustafa Kemal University (Approval no: 2018/7-2, 26/07/2018).

Informed Consent: N/A.

Peer Review: Externally peer-reviewed.

Author Contributions: Concept – F.K., A.K.T.; Design – F.K., A.K.T.; Supervision – F.K.; Analysis and/or Interpretation – A.K.T., T.K., P.P.A., F.K.; Literature Search – F.K., A.K.T.; Writing – F.K., A.K.T.

Acknowledgments: This study was extracted from thesis in Biochemistry Department of Veterinary Medicine Faculty by Ali Kazim Tambağ (master's degree student).

Conflict of Interest: The authors have no conflicts of interest to declare.

Financial Disclosure: This study was supported by Hatay Mustafa Kemal University Research Fund (grant number: 18.YL.071).

REFERENCES

1. Sherif IO, Al-Shaalan NH, Sabry D. Ginkgo biloba extract alleviates methotrexate-induced renal injury: new impact on PI3K/Akt/mTOR signaling and MALAT1 expression. *Biomolecules*. 2019;9(11). [CrossRef]
2. Bleyer WA. The clinical pharmacology of methotrexate: new applications of an old drug. *Cancer*. 1978;41(1):36-51. [CrossRef]
3. Khoshnoud S, Mohseni Kouchesfahani H, Nabiuni M. Evaluation of the protective effect of hydro-alcoholic extract of raspberry fruit on aquaporin1 expression in rats kidney treated by methotrexate. *Cell J*. 2017;19(2):306-313. [CrossRef]
4. Bath RK, Brar NK, Forouhar FA, Wu GY. A review of methotrexate-associated hepatotoxicity. *J Dig Dis*. 2014;15(10):517-524. [CrossRef]
5. Widemann BC, Adamson PC. Understanding and managing methotrexate nephrotoxicity. *Oncologist*. 2006;11(6):694-703. [CrossRef]
6. Ulusoy HB, Öztürk İ, Sönmez MF. Protective effect of propolis on methotrexate-induced kidney injury in the rat. *Ren Fail*. 2016;38(5):744-750. [CrossRef]
7. Al-Rashidy AH, Salem RR, Alhosary AA, et al. Role of erythropoietin in methotrexate-induced nephrotoxicity in adult male albino rats. *J Nephropharmacol*. 2018;7(2):156-163. [CrossRef]
8. Jalili C, Ghanbari A, Roshankhah S, Salahshoor MR. Toxic effects of methotrexate on rat kidney recovered by crocin as a consequence of antioxidant activity and lipid peroxidation prevention. *Iran Biomed J*. 2020;24(1):39-46. [CrossRef]
9. Dalaklioglu S, Sahin P, Ordueri EG, Celik-Ozenci C, Tasatargil A. Potential role of poly(ADP-ribose) polymerase (PARP) activation in methotrexate-induced nephrotoxicity and tubular apoptosis. *Int J Toxicol*. 2012;31(5):430-440. [CrossRef]
10. Kolli VK, Abraham P, Isaac B, Selvakumar D. Neutrophil infiltration and oxidative stress may play a critical role in methotrexate-induced renal damage. *Chemotherapy*. 2009;55(2):83-90. [CrossRef]
11. Sakalli ÇE, Tetiker H, İlhan Çelik Ö, Yılmaz N, Cığerci İH. Methotrexate-induced nephrotoxicity in rats: protective effect of mistletoe (*Viscum album* L.) extract. *Complement Med. Resources*. 2017;24(6):364-370.
12. Oktem F, Yılmaz HR, Ozguner F, et al. Methotrexate-induced renal oxidative stress in rats: the role of a novel antioxidant caffeic acid phenethyl ester. *Toxicol Ind Health*. 2006;22(6):241-247. [CrossRef]
13. Bozkurt M, Em S, Oktayoglu P, et al. Carvacrol prevents methotrexate-induced renal oxidative injury and renal damage in rats. *Clin Invest Med*. 2014;37(1):E19-E25. [CrossRef]
14. Asci H, Ozmen O, Ellidag HY, et al. The impact of gallic acid on the methotrexate-induced kidney damage in rats. *J Food Drug Anal*. 2017;25(4):890-897. [CrossRef]
15. Savran M, Cicek E, Doguc DK, et al. Vitamin C attenuates methotrexate-induced oxidative stress in kidney and liver of rats. *Physiol Int*. 2017;1-11. [CrossRef]
16. Ganeshpurkar A, Saluja AK. The pharmacological potential of Rutin. *Saudi Pharm J*. 2017;25(2):149-164. [CrossRef]
17. Kamalakkannan N, Stanely Mainzen Prince P. Rutin improves the antioxidant status in streptozotocin-induced diabetic rat tissues. *Mol Cell Biochem*. 2006;293(1-2):211-219. [CrossRef]
18. Korkmaz A, Kolankaya D. Inhibiting inducible nitric oxide synthase with rutin reduces renal ischemia/reperfusion injury. *Can J Surg*. 2013;56(1):6-14. [CrossRef]
19. Kamel KM, Abd El-Raouf OM, Metwally SA, Abd El-Latif HA, El-sayed ME. Hesperidin and rutin, antioxidant citrus flavonoids, attenuate cisplatin-induced nephrotoxicity in rats. *J Biochem Mol Toxicol*. 2014;28(7):312-319. [CrossRef]
20. Arjumand W, Seth A, Sultana S. Rutin attenuates cisplatin induced renal inflammation and apoptosis by reducing NFκB, TNF-α and caspase-3 expression in wistar rats. *Food Chem Toxicol*. 2011;49(9):2013-2021. [CrossRef]
21. Caglayan C, Kandemir FM, Yildirim S, Kucukler S, Eser G. Rutin protects mercuric chloride-induced nephrotoxicity via targeting of aquaporin 1 level, oxidative stress, apoptosis and inflammation in rats. *J Trace Elem Med Biol*. 2019;54:69-78. [CrossRef]
22. Lowry OH, Rosebrough NJ, Farr AL, Randall RJ. Protein measurement with Folin phenol reagent. *J Biol Chem*. 1951;193(1):265-275. [CrossRef]
23. Beutler E. *Red Cell Metabolism Manual of Biochemical Methods*. London: Academic Press; 1971:68-70.
24. Beutler E. Red cell metabolism. *Biochimie*. 1972;54(5-6):759-764. [CrossRef]

25. Mitani S, Yabuki A, Taniguchi K, Yamato O. Association between the intrarenal renin-angiotensin system and renal injury in chronic kidney disease of dogs and cats. *J Vet Med Sci.* 2013;75(2):127-133. [\[CrossRef\]](#)
26. Kutlu T, Alcigir G. Comparison of renal lesions in cats and dogs using pathomorphological and immunohistochemical methods. *Biotech Histochem.* 2019;94(2):126-133. [\[CrossRef\]](#)
27. Yuksel Y, Yuksel R, Yagmurca M, et al. Effects of quercetin on methotrexate-induced nephrotoxicity in rats. *Hum Exp Toxicol.* 2017;36(1):51-61. [\[CrossRef\]](#)
28. Mahmoud AM, Germoush MO, Al-Anazi KM, et al. Commiphora molmol protects against methotrexate-induced nephrotoxicity by up-regulating Nrf2/ARE/HO-1 signaling. *Biomed Pharmacother.* 2018;106:499-509. [\[CrossRef\]](#)
29. Korkmaz KS, Butuner BD, Roggenbuck D. Detection of 8-OHdG as a diagnostic biomarker. *J Lab precis. Med.* 2018;3:95.
30. Sanchez M, Roussel R, Hadjadj S, et al. Plasma concentrations of 8-hydroxy-2'-deoxyguanosine and risk of kidney disease and death in individuals with type 1 diabetes. *Diabetologia.* 2018;61(4):977-984. [\[CrossRef\]](#)
31. Liu CM, Ma JQ, Sun YZ. Quercetin protects the rat kidney against oxidative stress-mediated DNA damage and apoptosis induced by lead. *Environ Toxicol Pharmacol.* 2010;30(3):264-271. [\[CrossRef\]](#)
32. Akkoyun HT. The protective effect of quercetin Against to renal tissue damage induced carbontetrachloride in rat. *J Inst Sci Technol.* 2019;9(2):708-716. [\[CrossRef\]](#)
33. Minamiyama Y, Takemura S, Toyokuni S, et al. Amelioration of cisplatin toxicity by a fermented grain food product. *BioFactors.* 2002;16(3-4):105-115. [\[CrossRef\]](#)
34. Zhou H, Kato A, Miyaji T, et al. Urinary marker for oxidative stress in kidneys in cisplatin-induced acute renal failure in rats. *Nephrol Dial Transplant.* 2006;21(3):616-623. [\[CrossRef\]](#)
35. Babiak RM, Campello AP, Carnieri EG, Oliveira MB. Methotrexate: pentose cycle and oxidative stress. *Cell Biochem Funct.* 1998;16(4):283-293. [\[CrossRef\]](#)
36. Chauhan P, Sharma H, Singh S, Gupta YK, Kumar U. Attenuation of methotrexate-induced hepatorenal damage by Terminalia bellerica fruit extract in experimental rats. *Phcog Res.* 2018;10(3):301-308. [\[CrossRef\]](#)
37. Spencer NY, Stanton RC. Glucose 6-phosphate dehydrogenase and the kidney. *Curr Opin Nephrol Hypertens.* 2017;26(1):43-49. [\[CrossRef\]](#)
38. Xu Y, Osborne BW, Stanton RC. Diabetes causes inhibition of glucose-6-phosphate dehydrogenase via activation of PKA, which contributes to oxidative stress in rat kidney cortex. *Am J Physiol Renal Physiol.* 2005;289(5):F1040-F1047. [\[CrossRef\]](#)
39. Xu Y, Zhang Z, Hu J, et al. Glucose-6-phosphate dehydrogenase-deficient mice have increased renal oxidative stress and increased albuminuria. *FASEB J.* 2010;24(2):609-616. [\[CrossRef\]](#)
40. Pessôa BS, Peixoto EB, Papadimitriou A, Lopes de Faria JM, Lopes de Faria JB. Spironolactone improves nephropathy by enhancing glucose-6-phosphate dehydrogenase activity and reducing oxidative stress in diabetic hypertensive rat. *J Renin Angiotensin Aldosterone Syst.* 2012;13(1):56-66. [\[CrossRef\]](#)
41. Michiels C, Raes M, Toussaint O, Remacle J. Importance of S-glutathione peroxidase, catalase, and Cu/Zn-SOD for cell survival against oxidative stress. *Free Radic Biol Med.* 1994;17(3):235-248. [\[CrossRef\]](#)
42. Abd El-Twab SM, Hozayen WG, Hussein OE, Mahmoud AM. 18β-Glycyrrhetic acid protects against methotrexate-induced kidney injury by up-regulating the Nrf2/ARE/HO-1 pathway and endogenous antioxidants. *Ren Fail.* 2016;38(9):1516-1527. [\[CrossRef\]](#)
43. Armagan I, Bayram D, Candan IA, et al. Effects of pentoxifylline and alpha lipoic acid on methotrexate-induced damage in liver and kidney of rats. *Environ Toxicol Pharmacol.* 2015;39(3):1122-1131. [\[CrossRef\]](#)
44. Ansar S, Hamed S, AlGhosoon HT, AlSaedan RA, Iqbal M. The protective effect of rutin against renal toxicity induced by lead acetate. *Toxin Rev.* 2016;35(1-2):58-62. [\[CrossRef\]](#)
45. Kandemir FM, Ozkaraca M, Yildirim BA, et al. Rutin attenuates gentamicin-induced renal damage by reducing oxidative stress, inflammation, apoptosis, and autophagy in rats. *Ren Fail.* 2015;37(3):518-525. [\[CrossRef\]](#)