

## MR ANGIOGRAPHY IN EVALUATION OF ARTERIOVENOUS FISTULAS IN HEMODIALYSIS PATIENTS

### HEMODİYALİZ HASTALARINDA ARTERIOVENOZ FİSTÜLLERİN DEĞERLENDİRİLMESİ

Rıfki Ersoy\*, Caner Çavdar\*\*, Sedat Karademir\*\*, YavuzYeniçerioğlu\* Aykut Sifil\*, Ali Çelik ,  
Suat Menzilioğlu\*\*\*, Taner Çamsan\*

Department of Nephrology, Dokuz Eylül University, Turkey

\*\*Department of General Surgery, Dokuz Eylül University, Turkey

\*\*\*Pyramid Radiodiagnosis Center, Izmir, Turkey

#### SUMMARY

*Knowing the nature of anatomic disturbances in arteriovenous fistulas in hemodialysis patients is crucial in the management. Duplex ultrasonography and intraarterial angiography are the main imaging techniques applied in clinical practice. Despite being the gold standard, necessity of hospitalization, nephrotoxic properties of the radiocontrast medium used, exposure to radiation and invasive nature of the procedure limit the application of the intraarterial angiography. MR angiography, being an emerging technique in visualization of vascular structures, is devoid of aforementioned handicaps. We applied MR angiography to four patients and yielded successful visualization. We suggest that MR angiography might be a good alternative to intraarterial angiography in patients with residual renal function and when hospitalization was not desired.*

#### ÖZET

*Hemodiyaliz hastalarının tedavisinde arteriovenöz fistüllerdeki anatomik bozuklukların önemi bilinmektedir. Doppler ultrasonografi ve intraarteriyel anjiyografi kliniklerde sıklıkla uygulanan başlıca görüntüleme teknikleridir. Altın standart olmasına rağmen, hastaneye yatış gerekliliği, kullanılan radyokontrast maddenin nefrotoksik özellikleri, radyasyona maruz kalma ve işlemin invaziv oluşu intraarteriyel anjiyografi uygulamasını sınırlamaktadır. Vasküler yapıların görüntülenmesinde kullanılan ve yeni bir teknik olan manyetik rezonans (MR) anjiyografi ise bu olumsuzlukları taşımaz. Sunulan bu makalede rezidüel renal fonksiyonu olan fistül problemlili dört hastaya MR anjiyografinin rezidüel renal fonksiyonu olan ve hastaneye yatırılmak istenmeyen fistül problemlili hastalarda intraarteriyel anjiyografiye iyi bir alternatif olabileceğini düşünülmektedir.*

**Key Words:** hemodialysis, MR angiography, arteriovenous fistulas

**Anahtar Kelimeler:** hemodiyaliz, MR anjiyografi, arterio-venöz fistü

## INTRODUCTION

The anatomical disturbance of vascular access is one of the important causes of hemodialysis (HD) inadequacy (1,2). Early and accurate detection and management of the arterio-venous (AV) fistula dysfunction is crucial for prevention of hemodialysis inadequacy.

Gold standard in anatomical imaging of AV fistula is intraarterial angiography (IAA) (2,3). According to nature of the anatomic disturbance detected, management differs. Stent implantation, percutaneous angioplasty, surgical revision, graft implantation are the major alternatives (2,4,5). Necessity of hospitalization, invasive nature of the procedure, exposure to radiation and use of radiocontrast medium, which may result in further diminution of residual renal function, are the main handicaps of the IAA (3).

Recently magnetic resonant angiography (MRA) was applied more and more commonly in imaging of vascular structures (6,7). Even it is not used routinely in daily practice, it may be used in evaluation of AV fistulas (8,9). Non nephrotoxic properties of contrast medium used, avoidance of radiation exposure, administration of contrast medium through a peripheral vein and ability to be performed in outpatient settings are the main superiority of MRA over the conventional one (3).

In the present article, 4 cases undergone AV fistulae MRA for different indications are presented and the role of MRA in imaging of AV fistulas is considered.

### Case 1

The first patient was 67 year old man with end stage renal disease (ESRD) due to hypertensive nephrosclerosis. He has been on HD for a year. His vascular access was right Brescia-Cimino fistulae, providing maximum flow rate of 160-170 ml/min recently, although being 300 mL/min previously. For the determination of the problem, radiological imaging was planned. MRA was preferred to conventional angiography since the patient had previously undergone aortofemoral bypass grafting surgery which may face him to increased risk of atheroembolic complications. MRA disclosed multiple segmental atherosclerotic narrowing in the afferent (radial) artery while rest being within normal limits (fig 1,2). Since right upper extremity venous vasculature was normal in MRA, synthetic AV graft was inserted proximally.

### Case 2

A 57 year old man patient with ESRD due to diabetic nephropathy and with left antecubital AV fistula. Edema had developed in his left arm, meanwhile the blood flow rate through the fistulae was decreased. Radiological imaging was planned. Because of the presence 1500 cc/day residual urine output, MRA was preferred owing to its nonnephrotoxic properties. Distal segments of left brachial artery could not be visualized due to steal phenomenon. Proximal segment of the brachial vein was observed to be thrombosed while distal segments were arterialized (fig 3). Synthetic graft was implanted to ipsilateral side.

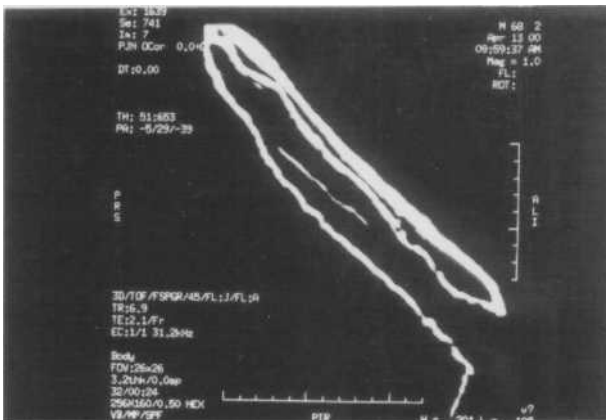### Case 3

A 60 year old woman was begun on HD because of acute renal failure following coronary artery bypass grafting surgery. Considering the case as chronic renal failure in the follow up, left antecubital fistula was performed. However after 4 months, HD treatment was stopped because of the improvement in renal functions. In the follow up, edema in the left upper extremity had developed. Upper extremity venous and arterial duplex sonography was within normal limits. Because of resolving acute renal failure, MRA was preferred to IAA to be able to visualize the proximal segments. MRA disclosed atherosclerotic irregularities in distal segments of left brachial artery, stenosis in left axillary and subclavian vein and venous collaterals and variceal dilatations around the stenotic sites (fig 4). Angioplasty was applied to involved segment.

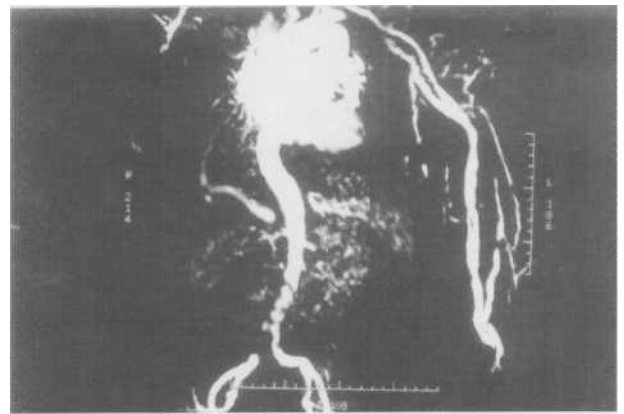
### Case 4

A 75 year old uremic woman with a previous history of multiple AV fistulae operations and catheter inserting was performed MRA to be able to determine the new vascular access strategy. Because of wide spread

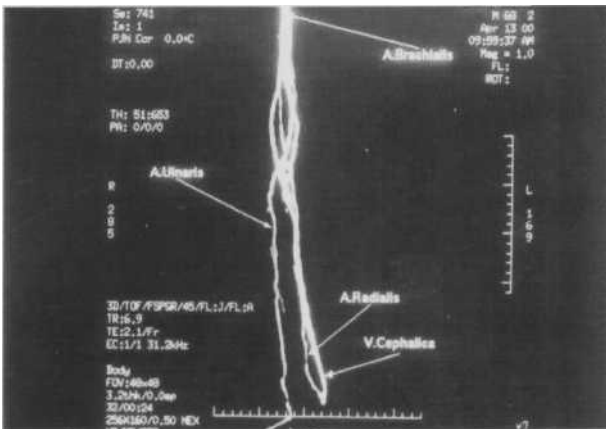
atherosclerotic disease and presence of residual urine output, MRA was the choice of the technique. In MRA, irregularities in distal segments of brachial arteries and stenosis distal to bifurcation of it, owing to atherosclerosis, was observed (fig 5). Additionally abdominal aorta and common iliac arteries and superior mesenteric artery were also observed to have wide-spread atherosclerotic irregularities. In turn arterio-venous graft was implanted to left antecubital fossa, unfortunately it have got to taken out to prevent severe steal. In the end, the patient was begun to be treated by means of peritoneal dialysis because of inability to create a new vascular access.



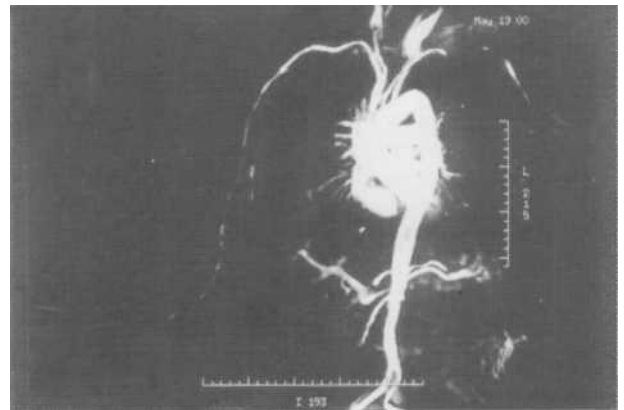
Resim 1-2:Multiple segmental atherosclerotic narrowing in the afferent artery, the other vascular structures are normal from different scopes.



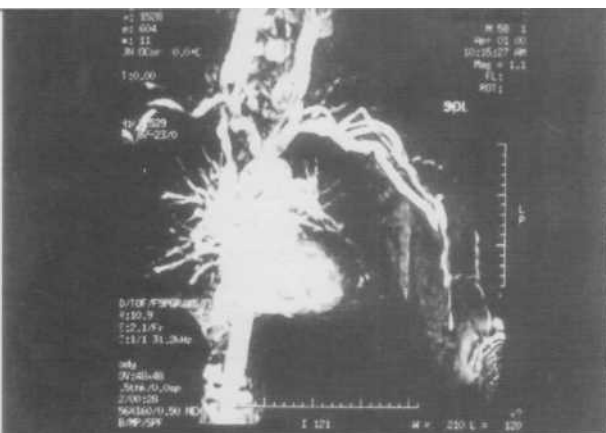Resim 4: Atherosclerotic irregularities in distal segments of brachial artery, stenosis of left axillary and subclavian vein and variceal dilatations and venous collaterals around.



Resim 1-2:Multiple segmental atherosclerotic narrowing in the afferent artery, the other vascular



Resim 5:Irregularities in distal segments of brachial arteries and stenosis distal to bifurcation of it, owing to atherosclerosis, was observed.



Resim 3: Brachial vein, proximal segments were thrombosed while distal segments were arterIALIZED

## DISCUSSION

Vascular access disturbances are among the important problems in HD patients (1,2). For adequate dialysis, AV fistula has to be large enough to provide sufficient flow rate and for cannulation (5). For effective dialysis, AV fistula should provide higher flow rates than that of pump rate (5). Problems pertaining to AV fistula may cause dialysis inadequacy and in turn increased morbidity, mortality, need for hospitalization and cost (2,3). Problems in AV fistula may be diagnosed by means of radiological imaging techniques besides physical examination, recirculation test and venous pressure measurements (4). Intraarterial angiography (IAA) is the gold standard in visualization of the AV fistula (1,3). Necessity of hospitalization and nephrotoxic properties of the radiocontrast medium used, exposure to radiation and invasive nature of the procedure are the main

handicaps of the IAA (3).

MRA is an emerging technique in visualization of vascular structures (6,7). Head and neck arteries and veins, large thoracic and abdominal vascular structures and lower extremity vessels are the main concern of the technique (3). Application of MRA in AV fistula of HD patients is first reported by Gehl et al in 1991 . They reported that it was with limited efficacy owing to technique and patients' compliance (10). Waldman et al in 1996 has reported that MRA was a suitable technique in visualization of HD vascular accesses (9). Lassy et al demonstrated in a study, considering flow gaps as a criteria for stenosis and thrombosis, MRA has yielded 1/19 false positive and 1/19 false negative results. Specificity and sensitivity were 86% and 92% respectively and they concluded that MRA was suitable technique in visualization of AV fistula in HD patients (8).

Considering data, we applied MRA for 4 patients with different indication to visualize AV fistula. By means of MRA besides AV fistula, more proximal and central venous structures were also visualized.

As a conclusion, MRA is of help in evaluation of vascular access in HD patients since it can visualize both arterial and venous parts of the fistula and it is a noninvasive, free of serious complications and easy to perform technique. MRA can be applied in patients with residual renal function and/or in high risk conditions for intraarterial interventions.

#### KAYNAKLAR

- 1- Conlon P J. Vascular access for hemodialysis. In: Johnson RJ, Feehally J, eds. *Comprehensive Clinical Nephrology*. Mosby, Spain: 2000;77.1-77.8
- 2- Besarab A, Prasurman R.P.K and Frinak S. Vascular access for hemodialysis. In: Malluche HH, Sawaya B.P, Hakim R.M and Sayegh M.H, eds. *Clinical Nephrology Dialysis and Transplantation*. Dustri-Verlag Dr. Karl Feistle, Germany: 1999;II-2:1-34.
- 3- Smith HJ. Magnetic resonance angiography. *Tidsskr Nor Laegeforen* 2000, 20; 120(8): 936-940
- 4- Porile JL, Richter M. Preservation of vascular access. *J Am Soc Nephrol* 1993;4: 997-1003.
- 5- Beathard GA, Settle SM, Shields MW. Salvage of the nonfunctioning arteriovenous fistula. *Am J Kidney Dis* 1999; 33(5): 910-916.
- 6- Gedroyc WM, Neerhut P, Negus R, et al. Magnetic resonance angiography of renal artery stenosis. *Clin Radiol* 1995; 50(7): 436-439.
- 7- Graves MJ. Magnetic resonance angiography. *Br J Radiol* 1997;70: 6-28.
- 8- Laissy JP, Menegazzo D, Debray MP, et al. Failing arteriovenous hemodialysis fistulas :assessment with magnetic resonance angiography. *Invest Radiol* 1999; 34 (3): 218-224
- 9- Waldman GJ, Pattynama PM, Chang PC, Verburgh C, Reiber JH, de Roos A. Magnetic resonance angiography of dialysis access shunts:initial results. *Magn Reson Imaging* 1996;14(2): 197-200.
- 10- Gehl HB, Bohndorf K, Gladziwa U, Handt S, Gunther RW. Imaging of hemodialysis fistulas; limitations of MR angiography. *J Comput Assist Tomogr* 1991; 15(2): 271-275.